

EPILEPSIA PARTIALIS CONTINUA AND INVOLUNTARY HAND MOVEMENT IN CHILDREN WITH SCHIZENCEPHALY: A CASE REPORT

Ardhini R¹, Bintoro AC¹, Husni A¹, Tugasworo D¹, Retnaningsih¹, Andhitara Y¹, Kurnianto A¹, and Budiman J¹.

¹Department of Neurology, Faculty of Medicine, Diponegoro University/ Dr. Kariadi General Hospital, Semarang Indonesia

Correspondence:

Rahmi Ardhini

Department of Neurology,

Faculty of Medicine,

Diponegoro University/ Dr. Kariadi General Hospital,

Semarang, Indonesia

Tel: 085640394577

Email: ardhini.rahmi@gmail.com

Abstract

Introduction: Schizencephaly is a rare congenital malformation of cerebral cortical development. Epilepsia partialis continua and movement disorders often display abnormal movements with overlapping phenomenology in schizencephaly. **Case report:** A 6-year-old-girl with normal prenatal and labor history, presented with continuous left hand movement since 1-year-old. Neurological examination showed left spastic hemiparesis. Electroencephalography (EEG) showed sharp and spike wave in right temporoparietooccipital, frontocentrotemporal and centroparietal region. Cerebral magnetic resonance imaging (MRI) showed a cleft in right frontal lobe extending to the right lateral ventricle classified as open-lip schizencephaly, and an agenesis of septum pellucidum leads to monoventricular features, and polymicrogyria. She was treated with valproic acid, haloperidol, and regular physiotherapy. **Conclusion:** This patient was diagnosed with schizencephaly from the anamnesis, physical examination, EEG, and cerebral MRI. The therapy of this patient was pharmacological treatment and physiotherapy.

Keywords: Athetosis, Epilepsia Partialis Continua, Schizencephaly

Introduction

Schizencephaly is a rare congenital disorder of cerebral cortical development, causing defect during neuronal cell migration in the second to fifth months of pregnancy (1–6). This disorder is characterized by linear, thickened clefts of the cerebral mantle and filled by cerebrospinal fluid; extending from the pial surface to the ventricles lined by heterotopic gray matter (5–8). Schizencephaly was first introduced by Wilmarth in 1887, then in 1946 by Yakovlev and Wadsworth who classified it into two types, type 1 or closed-lip and type 2 or open-lip (5–7,9). Type 1 or closed-lip has a closed cleft and is not related to the ventricular system, whereas type 2 or open-lip has an open cleft and is related to the ventricular system. The incidence of schizencephaly is 1.5:100,000 births, and 1:1650 in children with epilepsy. Type 2 is more common than type 1 (4,7). This disorder can be located in all areas of the brain, mostly in the frontal and parietal lobes, especially around the lateral sulcus or Sylvian fissure and it can be unilateral or bilateral (5,10,11).

Type 1 has mild neurological deficits such as mild hemiparesis and partial seizures, whereas in type 2 the symptoms that appear are usually more severe, such as severe

hemiparesis, mental retardation, growth disturbance, seizures and spasticity because the malformation is severe and irreversible (5,6).

There are no definite causes of schizencephaly until now, but several risk factors that are related to this disease are collagen type IV alpha 1 (COL4A1) mutation, empty spiracles homeobox 2 (EMX2) mutation, six homeobox 3 (SIX3) mutation, sonic hedgehog (SHH) mutation, pregnancy infection such as cytomegalovirus, the age of pregnant woman that is too young, history of poor antenatal care and drug abuse (5,8,12–15). Schizencephaly is often accompanied by other congenital abnormalities in 50–90% of cases, such as septo-optic dysplasia, agenesis of septum pellucidum and corpus callosum, polymicrogyria, pachigiria, heterotopia, and gastroschisis (4,16–18). In utero magnetic resonance (iuMR) is used for antenatal detection of brain abnormalities, including schizencephaly (19).

The diagnosis of schizencephaly is made by clinical symptoms, physical examination, and brain imaging. It is also important to ask about the risk factors and family history. The first choice of imaging study is cerebral magnetic resonance imaging (MRI) because it has

good resolution and does not use ionizing radiation. Differentiation between the substantia grisea and the substance of the alba will appear more clearly on MRI (4,5,20–22). Management of this disorder is conservative therapy and rehabilitation (5,23). Surgery is performed if there is hydrocephalus or intracranial hypertension (5,24).

Case presentation

A 6-year-old-girl came to the hospital presenting with continuous left hand movement since 1-year-old. The movement of the left hand and fingers was continuous, in the form of flexion and extension, adduction and abduction, without loss of consciousness that resembled athetosis and

epilepsy seizure. The movement disappeared during sleep. There was no history of pregnancy abnormality or disease in the mother, full-term birth and without complications. Physical examination showed no dysmorphic face and the head was mesocephal. On neurological examination, there was left spastic hemiparesis with motor strength of 4 and increased physiological reflexes. There were no cranial nerves palsy, no sensory and autonomic disturbance. There were no developmental delay and mental retardation.

Electroencephalography showed epileptogenic discharges on right frontocentrotemporal, right temporoparietooccipital, and right centroparietooccipital (Figure 1).

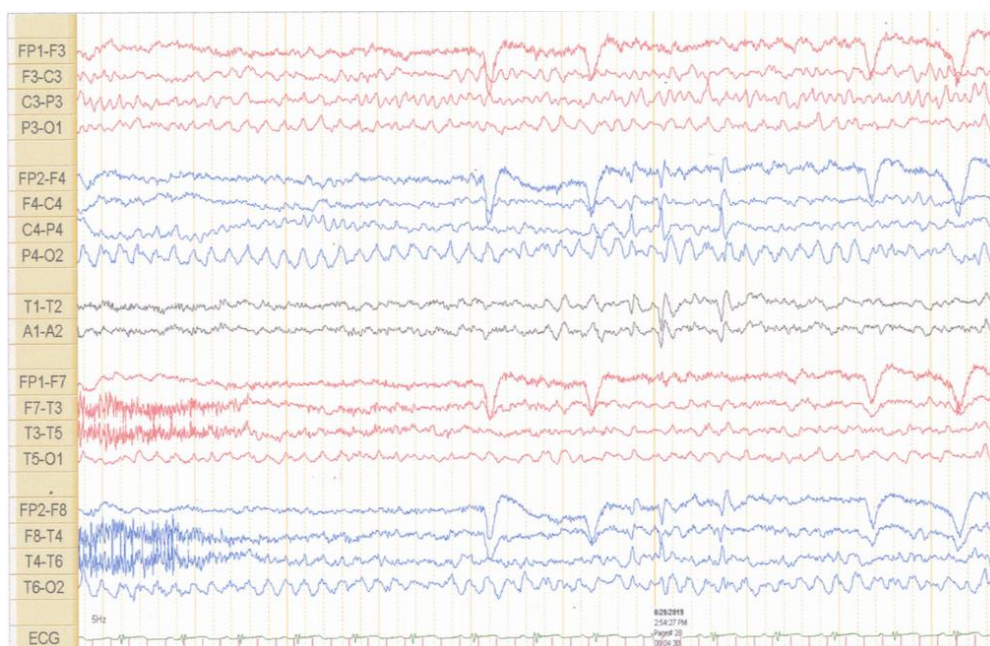


Figure 1: EEG showed the sharp and spike waves on the right frontocentrotemporal, right temporoparietooccipital, and right centroparietooccipital

Cerebral magnetic resonance imaging (MRI) showed a cleft in the right frontal lobe lined with gray matter, connecting the subarachnoid space with right lateral ventricle (the imaging of open-lip type) (Figure 2). There was no septum pellucidum structure so right and left ventricles were merged as monoventricle (suspect agenesis). There were excessive and shallow cortical folds in the left and right frontotemporoparietal lobe (polimicrogyria).

The therapy of the patient was valproic acid 125 mg/12 hours per oral (10 mg/kg body weight/day, divided into 2 doses), haloperidol 0.5 mg/12 hours per oral, and regular physiotherapy (occupational therapy). After the therapy, the movement of the hand was reduced (amplitude and frequency). The therapy was given over 1 year.

Discussion

This case report presents a 6-year-old-girl with chief complaint of continuous left hand movement. The movement was flexion, extension, adduction, and abduction. The movement did not involve the forearm and upper arm. The manifestation in this patient appeared as an athetosis type of movement disorder but also resembled a continuous focal epileptic seizure called *epilepsia partialis continua*.

Athetosis, derived from the Greek language which means not fixed or changing, is a movement disorder characterized by the inability to maintain the parts of the body, such as fingers, hands, tongue or others body part in one position, thus causing a slow and continuous winding movement (25,26). While *epilepsia partialis continua* is defined as

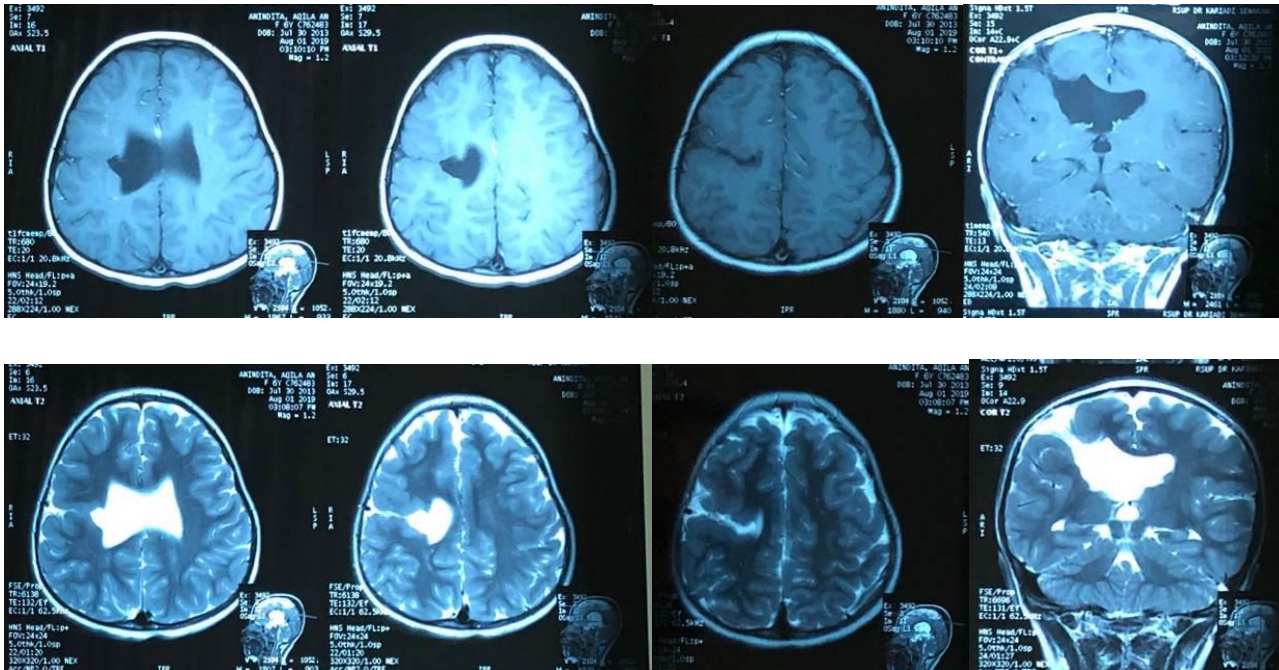


Figure 2: Cerebral MRI, T1 (above) dan T2 (bottom)

a continuous epilepsy seizure (status epilepticus) in the form of focal motor onset seizure lasting for more than 60 minutes and recurring at intervals of less than 10 seconds. The movements that appear are stereotypic, can involve one muscle, a group of muscles, or an extremity (27).

Epilepsia partialis continua and movement disorder are 2 conditions with similar and often overlapping symptoms, explaining the continuous movement of the hands in this patient. This patient needed additional examination to establish the diagnosis, such as EEG and cerebral MRI. Cerebral MRI showed an open-lip type schizencephaly, agenesis of septum pellucidum, and polymicrogyria. The presence of an open-lip type schizencephaly in this patient explains the manifestation of epilepsia partialis continua and spastic sinistra hemiparesis due to abnormalities in the motor cortex of the frontal lobe. There is a cleft filled with cerebrospinal fluid which extends from the subarachnoid cavity to the right lateral ventricle in the motor cortex of the right frontal lobe.

Clinical manifestation in this patient is classified as mild, which is not in accordance with the literature which states that the seizure of epilepsy and mild motor weakness are more common in type 1, whereas type 2 have worse and irreversible clinical symptoms, and often accompanied by mental retardation and growth disorders, which were not found in this patient. Other literature also stated that the presence of polymicrogyria and heterotopia also led to the manifestation of epilepsia partialis continua (5,6,19,28,29).

Agenesis of septum pellucidum and polymicrogyria that were found in this patient are two disorders that often accompany schizencephaly. Septum pellucidum is a structure found in the midline of the brain between

the 2 cerebral hemispheres that separates the 2 lateral ventricles. The structure is in the form of a thin wall from 2 thin membrane consisting of the substantia grisea and alba, attached to the corpus callosum in the superoanterior and fornix in the inferoposterior (30). Whereas polymicrogyria is a cerebral cortex that looks wavy due to the excessive number of small sized gyrus that is limited by shallow sulcus. Polymicrogyria can occur in all areas, but is often found in the frontal cortex. This disorder often causes motoric and intellectual disturbance and seizures (31–33).

Until now, there are only a few case reports similar to this case. From these cases, the manifestation that arises is the continuous movement in the hands in accordance with dystonia or athetosis. Marinelli et al. (2012) and Zyss et al. (2007) reported that the movement disappeared during sleep, similar to this patient.(6,29) Friedman et al. (1996) reported that schizencephaly can manifest as athetosis.(34) Athetosis appears as a continuous and slow extension - pronation and flexion - supination movement of the hand. The mechanism of movement disorders in schizencephaly is not yet known, but it is believed that this condition is caused by reduced number of periventricular neurons including in the basal ganglia (26,28,34).

The presence of epileptogenic waves in several areas of the brain including the right frontal region on EEG examination is clinically appropriate in this patient in the form of focal seizures that support the diagnosis of epilepsia partialis continua.

The authors considered that the diagnosis of this patient is epilepsia partialis continua, supported by the presence of schizencephaly and polymicrogyria on MRI and the finding of epileptogenic discharges in the EEG. Although

this manifestation is similar to athetosis, we cannot find the etiology and pathological processes that support the diagnosis of movement disorders.

Conclusion

This patient was diagnosed with schizencephaly from the anamnesis, physical examination, EEG, and cerebral MRI. The therapy of this patient was pharmacologic treatment and physiotherapy.

Acknowledgement

None

Competing interests

The authors declare that there is no conflict of interest.

Ethical Clearance

Written informed consent was taken from patient's parent for case discussion and publication.

Financial support

None

References

- Shin C, Kwon YN, Ahn T-B, Lee D, Ahn TB. Incongruent hemiatrophy and hemiparkinsonism in a patient with schizencephaly. *Clin Neurol Neurosurg.* 2018;175:106–7.
- Tanwir A, Bukhari S, Shamim MS. Frontoethmoidal encephalocele presenting in concert with schizencephaly. *Surg Neurol Int.* 2018;9(1):246.
- Harada T, Uegaki T, Arata K, Tsunetou T, Taniguchi F, Harada T. Schizencephaly and porencephaly due to fetal intracranial hemorrhage: A report of two cases. *Yonago Acta Med.* 2017;60(4):241–5.
- Ugboma E, Agi C. Schizencephaly: A case report and review of literature. *Niger Postgr med J.* 2016;23(1):38–40.
- Halabuda A, Klasa L, Kwiatkowski S, Wyrobek L, Milczarek O, Gergont A. Schizencephaly – diagnostic and dilemmas. *Childs Nerv Syst.* 2015;31(4):551–6.
- Marinelli L, Bonzano L, Saitta L, Trompetto C, Abbruzzese G. Continuous involuntary hand movement and schizencephaly: epilepsy partialis continua or dystonia? *Neurol Sci.* 2012;33(2):335–8.
- Tyř F, Brunovský M, ěulcová K, Kohútová B, Ryznarová Z, Kopeček M. Latent Schizencephaly with psychotic phenotype or schizophrenia with schizencephaly? A case report and review of the literature. *Clin EEG Neurosci.* 2019;50(1):13–9.
- Watanabe J, Okamoto K, Ohashi T, Natsumeda M, Hasegawa H, Oishi M, *et al.* Malignant hyperthermia and cerebral venous sinus thrombosis after ventriculoperitoneal shunt in infant with schizencephaly and COL4A1 mutation. *World Neurosurg.* 2019;127:446–50.
- Dhiman D, Mahajan SK, Sharma S, Raina R, Pradesh H, Pradesh H, *et al.* A patient with schizencephaly and agenesis of corpus callosum with no neurological deficits. *J Neurosci Rural.* 2018;79(1):68–72.
- Brant W, Helms C. *Fundamentals of diagnostic radiology*, 5th edition. Philadelphia: Lippincott Williams and Wilkins (LWW); 2018.
- Hunter A. Brain. In: Stevenson R, Hall J, eds. *Human malformations and related anomalies*. New York: Oxford University Press. 2006:648–51.
- Inan C, Sayin NC, Gurkan H, Atli E, Gursoy Erzincan S, Uzun I, *et al.* Schizencephaly accompanied by occipital encephalocele and deletion of chromosome 22q13.32: A case report. *Fetal Pediatr Pathol.* 2019;38(6):496–502.
- Sunilkumar D, Nagarajan K, Kiran M, Manjubashini D, Sabarish S. Persistent falcine sinus with temporo-occipital schizencephaly: A case report with a review of literature in relation to the undeveloped vein of Galen and/or straight sinus. *Child Nerv Syst.* 2019;36(2):417–21.
- Sato Y, Shibasaki J, Aida N, Hiiragi K, Kimura Y, Akahira-Azuma M, *et al.* Novel COL4A1 mutation in a fetus with early prenatal onset of schizencephaly. *Hum Genome Var.* 2018;5(4):1–4.
- Pascual-Castroviejo I, Pascual-Pascual SI, Velazquez-Fragua R, Viaño J, Quiñones D. Schizencephaly: A study of 16 patients. *Neurologia.* 2012;27(8):491–9.
- Biswas A, Furruqh F, Thirunavukarasu S, Vivekandan R. Cortical clefts and cortical bumps: A continuous spectrum. *J Clin Diagn Res.* 2016;10(7):TD01–2.
- Howe DT, Rankin J, Draper ES. Schizencephaly prevalence, prenatal diagnosis and clues to etiology: A register-based study. *Ultrasound Obs Gynecol.* 2012;39(1):75–82.
- Sarnat H, Curatolo P. *Malformations of the nervous system*, 1st edition. Edinburg: Elsevier. 2007:235.
- Griffiths PD. Schizencephaly revisited. *Neuroradiology.* 2018;60(9):945–60.
- Jbili N, Mounir K, Kechna H, Bibiche L, Laoutid J, Diai A, *et al.* A rare case of super-refractory epileptic status in pregnant woman: Schizencephaly, Vol. 38. *Anaesth Intensive Care Med: Elsevier Masson SAS.* 2019:195–8.
- Kamble V, Lahoti AM, Dhok A, Taori A, Pajnigara N. A rare case of schizencephaly in an adult with late presentation. *J Fam Med Prim Care.* 2017;6(2):169–70.
- Rege S, Patil H. Bilateral giant open-lip schizencephaly: A rare case report. *J Pediatr Neurosci.* 2016;11(2):128–30.
- Penny SM, Klapp K, Sturdivant C. Literature review: Sonographic diagnosis of schizencephaly. *JDMS.* 2010;26(4):183–7.
- Okunlola AI, Olowoyo P, Okunlola CK, Babalola OF. Adult-onset seizure disorder secondary to

- schizencephaly. *Asian J Neurosurg.* 2020;15(1):159–61.
25. Yilmaz S, Mink JW. Treatment of chorea in childhood. *Pediatr Neurol.* 2020;102:10–9.
 26. Ropper AH, Adams RD, Victor M, Samuels MA. Abnormalities of movement and postures caused by disease of the basal ganglia. In: Ropper A, Samuels M, Klein J, eds. *Adams and Victor's Principles of Neurology.* 10th ed. New York: McGraw-Hill. 2014:64–80.
 27. Mameniškienė R, Wolf P. Epilepsia partialis continua: A review. *Seizure.* 2017;44:74–80.
 28. Kopyta I, Skrzypek M, Raczkiwicz D, Bojar I, Sarecka-Hujar B. Epilepsy in paediatric patients with schizencephaly. *Ann Agric Env Med.* 2020;27(2):279–83.
 29. Zyss J, Xie-Brustolin J, Ryvlin P, Peysson S, Beschet A, Sappey-Marinié D, *et al.* Epilepsia partialis continua with dystonic hand movement in a patient with a malformation of cortical development. *Mov Disord.* 2007;22(12):1793–6.
 30. Chun YK, Kim HS, Hong SR, Chi JG. Absence of the septum pellucidum associated with a midline fornical nodule and ventriculomegaly: A report of two cases. *J Korean Med Sci.* 2010;25(6):970–3.
 31. Braga VL, da Costa MDS, Riera R, dos Santos Rocha LP, de Oliveira Santos BF, Matsumura Hondo TT, *et al.* Schizencephaly: A review of 734 patients. *Pediatr Neurol.* 2018;87:23–9.
 32. Hung PC, Wang HS, Chou ML, Lin KL, Hsieh MY, Chou IJ, *et al.* Schizencephaly in children: A single medical center retrospective study. *Pediatr Neonatol.* 2018;59(6):573–80.
 33. Lee J. Malformation of cortical development: Genetic mechanism and diagnostic approach. *Korean J Pediatr.* 2017;60(1):1–9.
 34. Friedman J, Stone W. Delayed-onset dystonia secondary to unilateral schizencephaly. *Mov Disord.* 1996;11(2):221–2.