

DENSE BONE ISLANDS: A CASE SERIES AND IMPLICATIONS FOR ORTHODONTIC TREATMENT

Ashari A¹, Oliver GR², Rajaran JR³, Joann YSM¹, and Jaafar FL¹.

¹Department of Family Oral Health, Faculty of Dentistry, Universiti Kebangsaan Malaysia, Kuala Lumpur, Malaysia

²Gloucestershire Royal Hospital, Gloucester, United Kingdom

³Department of Oral & Maxillofacial Surgery, Faculty of Dentistry, Universiti Kebangsaan Malaysia, Kuala Lumpur Malaysia

Correspondence:

Dr. Asma Ashari,

Lecturer & Orthodontist DUG54,

Department of Family Oral Health, Faculty of Dentistry,

Universiti Kebangsaan Malaysia,

Kuala Lumpur, Malaysia

Email: asmaashari@ukm.edu.my

Abstract

Dense bone islands (DBI) are benign intra-bony osteosclerotic lesions that are often asymptomatic and found incidentally on dental radiographs. DBI in patients requiring orthodontic treatment may influence the success of tooth movement through the lesion, the implications for the management of anchorage, possible increased risk of root resorption or whether the lesion needs to be excised prior to orthodontic treatment. Although there are many case reports pertaining to DBIs, very few involve those requiring orthodontic treatment. The diagnosis, management, and outcomes of three cases diagnosed with DBI are described in which orthodontic treatment has been undertaken in patients with DBIs.

Keywords: Dense Bone Islands, Orthodontic, Space Closure

Introduction

Intra-bony osteosclerotic lesions of the jaws can be classified based on their aetiology being neoplastic, inflammatory or idiopathic in origin. Neoplastic and inflammatory are easily identifiable when linked with certain aetiological factors (e.g. chronic periapical infection in inflammatory lesions) and clinical symptoms which require definitive intervention (1, 2). Conversely, idiopathic intra-bony osteosclerotic lesions are usually asymptomatic, such that the lesions are often only identified incidentally on dental-pantomogram (DPT) radiographs taken to facilitate orthodontic diagnosis (3, 4). Intra-bony osteosclerotic lesions of idiopathic origin are identified with many different names in the literature such as osteosclerosis, condensing osteitis, bone eburnation, bone scar, osteopetrotic scar, periapical osteopetrosis, enostosis, sclerotic bone, socket sclerosis, bone whorl or dense bone island (5, 6). The authors prefer the term 'Dense Bone Island' (DBI) due to its simplicity in accurately describing the lesion, being easier for lay people to understand, as well as seeming less alarming to patients.

The prevalence of DBIs is reported to be 3.1-31% (7, 8) and can be found in any type of bone, although the highest incidence is in long bones, the pelvis and ribs (9). In the maxillofacial region, they are more prevalent in the body of the mandible, especially in the premolar region (10, 11).

They are more common in adults than children and have no sexual predisposition (10, 12, 13).

Achieving a diagnosis of DBI is by exclusion from other similar looking bony lesions such as fibrous dysplasia or focal cemento-osseous dysplasia.

DBIs are characterized by an irregular, round or elliptical radiopacity that is well defined from the normal bone around them (12, 14, 15). They have a homogeneous radio-density and sclerotic focus in the cancellous bone with thorny radiation or pseudopodia on the peripheral area that blend with the host bone trabecular (16). DBI lesions are frequently asymptomatic and found at the periapical or inter-radicular area as an incidental finding with limited change in size over time.

Advanced 3-Dimensional imaging, such as a cone-beam computed tomography (CBCT) in certain cases is indicated when there are unusual radiographic observations. In the British Orthodontic Society radiographic guidelines, a CBCT is advised in cases where there is a potential for the findings to inform or alter the prescription of treatment (17). CBCT can provide accurate information relating to the proximity of the lesion to the surrounding dentition, diagnosis of pathology such as root resorption and support differential diagnosis. In cases where the findings of radiographic images such as DPT and periapical (PA) is sufficient for

diagnosis and will not change the treatment plan, a CBCT would not be necessary.

In atypical cases, an incisional biopsy of the lesion is indicated to confirm the diagnosis. For example, this could be when there are clinical signs of possible damage to adjacent structures. Histological examination of hematoxylin and eosin-stained tissue sections without the need of immunohistochemical staining can be used to identify the histological entity of the tumour. Histologically, DBIs are composed of calcified and dense tissue without marrow space and are not associated with atypical nuclei or mitosis which represents neoplasm (18).

Since most DBIs are asymptomatic and benign in nature, they are managed conservatively. Surgical removal would risk damage to adjacent structures such as the dentition or the inferior alveolar nerve. Furthermore, complete removal of the lesion may not prevent recurrence (19). The most suitable management is long term periodic clinical and radiographic follow up to monitor for changes in clinical symptoms or radiographic appearance.

Within orthodontics, concerns may arise when the planned path for orthodontic tooth movement traverses the DBI. The concerns being whether the tooth can be moved across the lesion and at what rate, the implications for the management of orthodontic anchorage, possible increased risk of root resorption or whether the lesion needs to be removed prior to orthodontic treatment.

To the best of the authors knowledge currently there are no studies pertaining to DBI management in orthodontic treatment. Although there are many case reports pertaining to DBI, very few relate to incidental findings where the DBI would affect orthodontic treatment (3, 20). Other case reports involving orthodontic treatment looking at other bony anomalies such as florid cemento-osseous dysplasia or focal sclerosing osteitis have been reported (21, 22), however, they are not DBI lesions and differ in terms of aetiology and makeover.

The main objective is for the reader to understand the clinical implications of performing orthodontic tooth movement in areas of DBI. Three cases presenting with DBIs requiring orthodontic treatment are described including their diagnosis, management, and outcomes.

Case report 1

Case summary

A 23-year-old medically fit and well Chinese female presented complaining of difficulty chewing and speaking. On examination, she presented with a Class II division 1 malocclusion on a skeletal II pattern with vertical maxillary excess complicated by hypodontia of the lower right second premolar. In occlusion the overjet was 12 mm with an increased and complete overbite, buccal crossbite between UR6 and LR6 with no displacement. Molar relationship was Class I on the right and left was Class II full unit. Oral hygiene was fair (Figure 1).

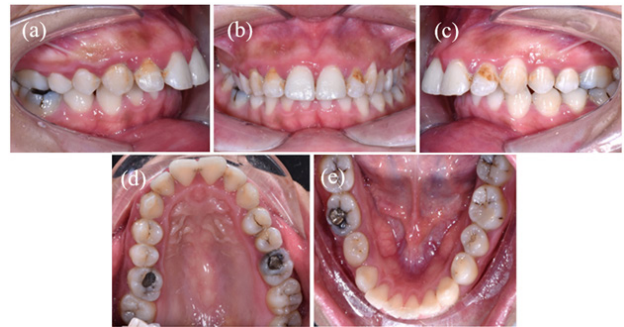

Figure 1: Case 1: Clinical intraoral photographs prior to starting orthodontic treatment showing lateral (a and c), anterior (b), palatal (d) and lingual (e) views

A DPT revealed a radio-opaque lesion of 10 mm x 6 mm between the roots of LR6 (Figure 2). There was a slight radiolucency in the middle of the lesion, which is unusual for DBI as they are usually homogenous. Due to the lesion's unusual appearance and an overlapping of the lesion with the LR6 lamina dura, a CBCT was taken to further investigate the extent of the lesion along with the presence of any root resorption or pathology of LR6. The CBCT revealed two lesions. The first lesion was a radiopaque lesion measuring 10 mm x 6 mm x 7 mm located between the apices of LR6 and is in contact with both the mesial and distal apices. It includes a radiolucent target lesion in the centre that was incorporated within the buccal and lingual cortex of the mandible lingually (Figure 3). No resorption of the molar roots was noted. The second lesion was a radiopaque lesion beneath the apex of LR3 measuring 5 mm x 5 mm x 5 mm (Figure 3). Electric pulp testing confirmed LR3 and LR6 were both vital. Both lesions were diagnosed as DBIs.

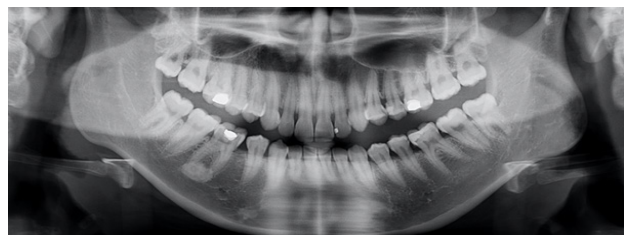

Figure 2: Case 1: Pre-treatment DPT prior to starting orthodontic treatment. Radiopacity present at periapical area of LR6 and beneath LR3

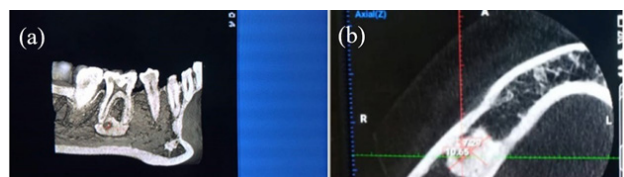


Figure 3: Case 1: CBCT sections of radiopacities adjacent to LR3 and LR6 prior to orthodontic treatment showing sagittal plane (a) and axial plane (b) views. The CBCT clearly shows the radiolucent area in the middle of the DBI

Treatment objectives

Considering the absence of root resorption and the small overlap of the DBI with the LR6, the plan was to proceed with orthodontic treatment which would involve a small mesial movement of LR6 forward due to the spacing between the LR4 and LR3. The orthodontic plan involved upper arch expansion with a quad-helix appliance followed by extraction of the UR4 and UL4, lower arch interproximal reduction and full upper and lower pre-adjusted edgewise appliances (022" x 028", MBT prescription) supported with temporary anchorage devices (TADs) to intrude the upper labial segment.

Consent was obtained from the patient regarding the degree of uncertainty on how the DBI would influence orthodontic treatment being failure to close all spaces, the duration of treatment, an increased risk of root resorption and pulp devitalization. In light of the planned tooth movement and large occlusal restoration in the LR6, regular recording of pulp sensibility testing with ethyl-chloride and electro-pulp testing (3 monthly) and periapical (PA) radiographs (Bi-annual) were performed.

Treatment progress in area of DBI

A PA radiograph taken mid-treatment shows the lower right first molar to be moving away from the radiopaque lesion with the intact lamina dura and no signs of root resorption (Figure 4). The patient did not complain of any pain and no other pathology was noted. The near-end PA radiograph shows the LR6 has moved across the DBI with no signs of root resorption (Figure 5). Space closure occurred without incident (no difficulties were encountered during this process) and at a normal rate until all space was closed (Figure 6). The LR6 tested positive to ethyl-chloride and electro-pulp testing throughout treatment.

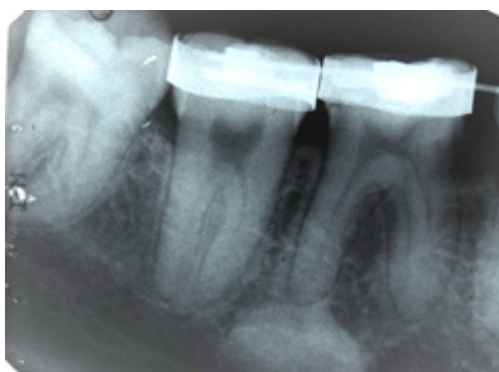

Figure 4: Case 1: Periapical radiograph (PA) of LR6 during space closure

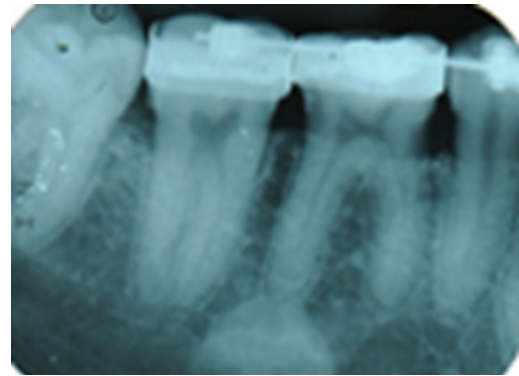


Figure 5: Case 1: PA of LR6 after space closure completed

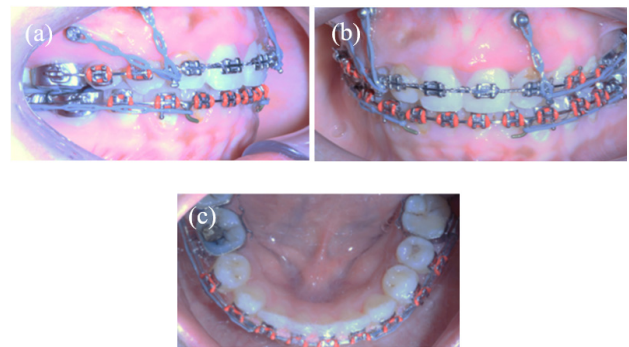


Figure 6: Case 1: Clinical intraoral photographs once spaces have closed and LR6 moved forward mesially showing lateral (a), anterior (b) and lingual (c) views

Case report 2

Case summary

A 17-year-old Malay female presented with Class I malocclusion on a skeletal I pattern with average vertical proportions. The malocclusion was complicated by poor prognosis first permanent molars, severe upper and lower arch crowding, upper dental centreline 2.5 mm to the right, crossbite involving UR2-UL2 associated with an anterior mandibular displacement (Figure 7). The molar relationship was Class I on right and Class III ¼ on left. The LL5 was distally tipped and impacted against LL6. A DPT showed a radiopacity of approximately 10 mm x 20 mm localised around the distal aspect of the apex of LL5 (Figure 8). A PA (Figure 9) and sectional CBCT (Figure 10) of the area confirmed the intact lamina dura and periodontal ligament (PDL) of the LL5.

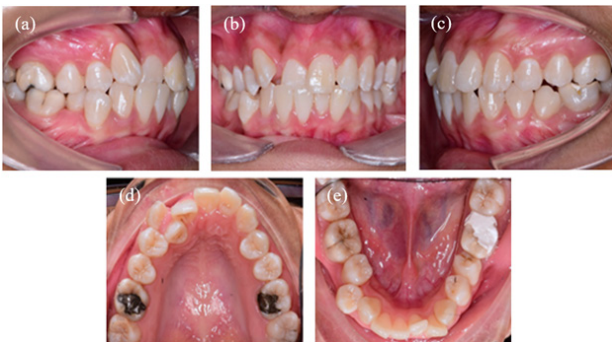


Figure 7: Case 2: Clinical intraoral photographs prior to starting orthodontic treatment showing lateral (a and c), anterior (b), palatal (d) and lingual (e) views

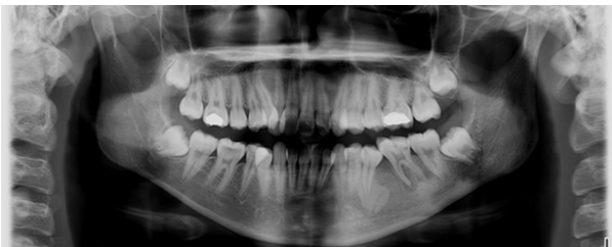


Figure 8: Case 2: Pre-treatment DPT prior to starting orthodontic treatment. Radiopacity present at periapical area of LL5

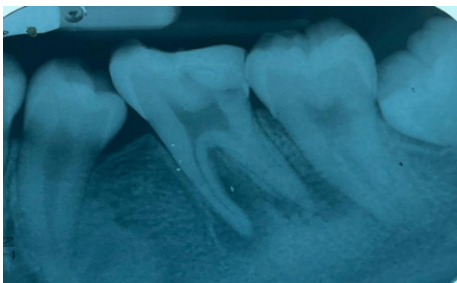

Figure 9: Case 2: PA of showing radiopacity present at periapical area of LL5 prior to starting orthodontic treatment. LL6 was extracted prior to orthodontic treatment

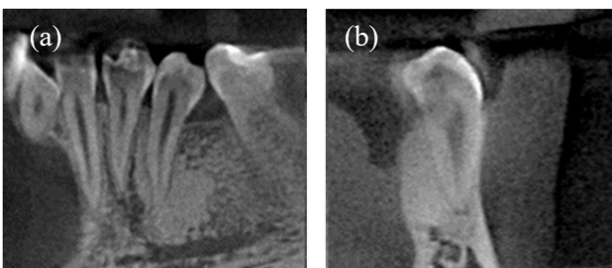


Figure 10: Case 2: Sagittal plane (a) and coronal plane (b) views of CBCT in area of osteosclerotic lesion

Treatment objectives

Following a review with the oral and maxillofacial surgery department, the radiopacity was biopsied as the distally tipped LL5 raised concerns of the possibility of an actively expanding lesion, such as fibro osseous lesions. An incisional biopsy of the lesion was performed and histological analysis of section (4) (5/18-1) (Figure 11) showed a vital bone trabecular within a mildly inflamed fibrofatty connective tissue. No prominent osteoblastic rimming was seen. Section (3) (5/18-2) (Figure 12) showed one fragment of vital mature bone with very focal fibrocellular tissue attachment. The findings were in keeping of a DBI.

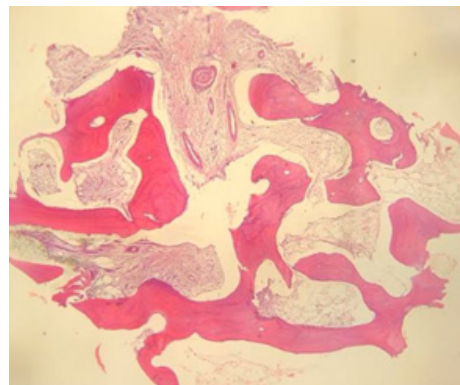


Figure 11: Case 2: Histological section (4) (5/18-1)

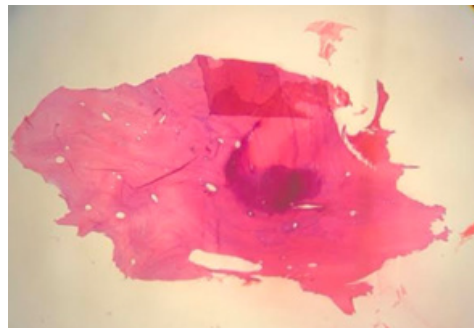


Figure 12: Case 2: Histological Section (3) (5/18-2)

Orthodontic treatment involved anchorage reinforcement with both Nance palatal arch and lower lingual arch, extraction of all the poor prognosis first permanent molars, followed by full upper and lower pre-adjusted edgewise appliance (022" x 028") MBT prescription. Consent was obtained from the patient and the same risks of treatment and possible compromised result was given as per Case 1.

Treatment progress in area of DBI

Tooth movements were initially slow on the lower left region most likely due to the DBI, which was expected; however, with anchorage reinforcement (banding of the LL7), light forces and longer activation period, LL4 and LL5 were retracted successfully over an 11-month period. On the lower right, space closure was initially

faster; however, total space closure was also completed within the same 11-month period. Periodic pulp testing of ethyl-chloride and electro-pulp testing (3 monthly) did not find any abnormalities to these teeth. Periodic radiographic monitoring following space closure showed mild to moderate root resorption on the LL4 and LL5 (Figure 13) with no clinical symptoms present. The patient was informed of the root resorption and reassured it is unlikely for the prognosis of the teeth to be compromised in the long-term providing a satisfactory level of oral hygiene is maintained. From the near-end DPT post-space closure and intraoral photographs at near-end and post orthodontic treatment (Figure 14, 15, 16), bodily movements of the teeth has taken place and was not affected as they moved through the DBI lesions.

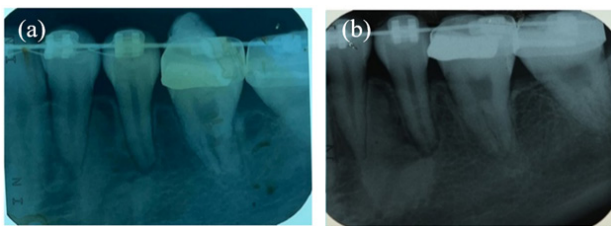


Figure 13: Case 2: PA (a) right after space closure completed, (b) 6 months after space closure completed, showed no significant progression of the mild root resorption of the LL5 and LL4. Teeth respond normally to pulp testing with no clinical sign and symptoms at each interval

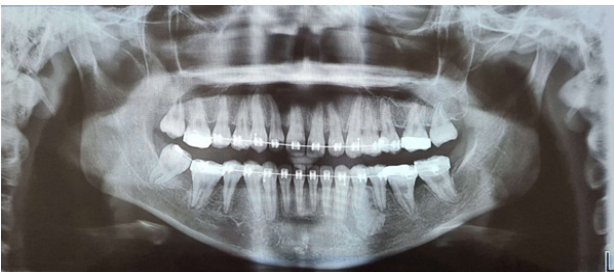

Figure 14: Case 2: DPT after space closure completed

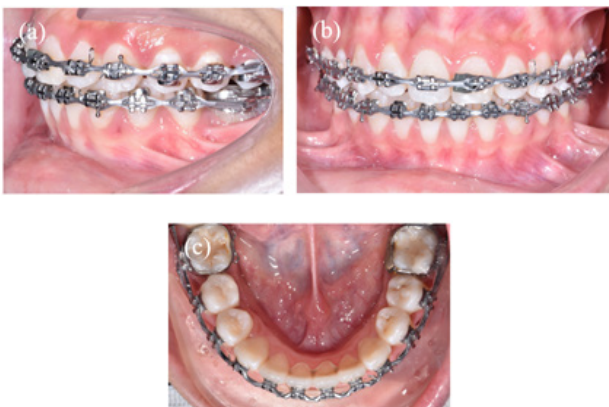

Figure 15: Case 2: Clinical intraoral photographs after space closure completed showing lateral (a), anterior (b) and lingual (c) views

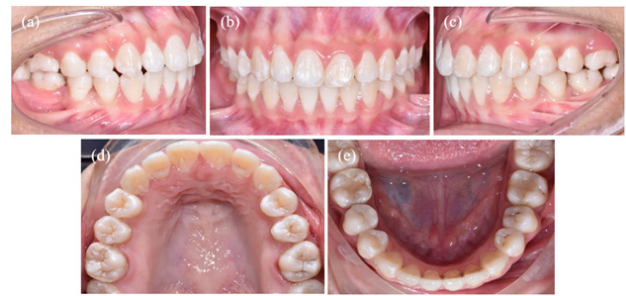

Figure 16: Clinical intraoral photographs of Case 2 after debond showing lateral (a and c), anterior (b), palatal (d) and lingual (e) views

Case report 3

Case summary

A 23-year-old, healthy Malay female presented with a Class I incisor relationship on a skeletal I pattern with average vertical proportions. The malocclusion was complicated by hypodontia of UR2 and UL2, mild spacing of the upper and moderate crowding of lower arches, lower midline shifted to the left, anterior crossbite on UL3 with no mandibular displacement (Figure 17).

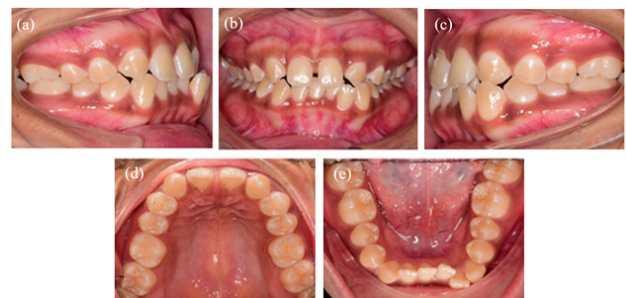

Figure 17: Case 3: Clinical intraoral photographs prior to starting orthodontic treatment showing lateral (a and c), anterior (b), palatal (d) and lingual (e) views

Investigations

A pre-treatment DPT showed a radio-opaque lesion present near the apex of LL3 (Figure 18). Radiographically, the lesion was placed apical to LL3, measuring 20 mm x 30 mm and there was no tilting or displacement of roots seen. The outline of the PDL and apex of the tooth was also clearly seen without any radio-opacities overlapping any tooth structure. Clinically there was no buccal-lingual bone expansion in the LL3 region. After review with oral and maxillofacial surgery, the lesion was considered a DBI and did not require any further radiographic investigation prior to starting orthodontic treatment. Once orthodontic treatment commenced, sensibility testing was done every three months during orthodontic treatment where both LL3 and LL4 were vital at all stages.

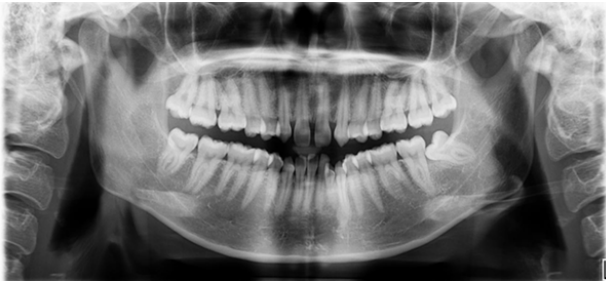

Figure 18: Case 3: Pre-treatment DPT showing radiopacity present at periapical area of LL5

Treatment objectives

Considering the DBI diagnosis, the plan for the area of DBI was to proceed with tooth movement along the DBI, where the extraction of LL4 would involve relieving crowding by moving LL3 and LL2 posteriorly across the DBI. Consent was obtained from the patient and the same risks of treatment and possible compromised result was given as per Case 1. The overall orthodontic treatment plan involved extraction of LR4, LL4 and followed by upper and lower pre-adjusted Edgewise appliance (022" x 028") MBT prescription. The importance of excellent oral hygiene throughout treatment was stressed to the patient.

Treatment progress in area of DBI

The LL3 was retracted successfully using sliding mechanics to relieve the anterior crowding. The lower left second permanent molar was banded to reinforce posterior anchorage. As expected, tooth movement was initially slower on the lower left region; however, with light forces and longer activation period, LL3 was in good alignment with the rest of the teeth. Periodic clinical and radiographic monitoring did not find any abnormalities to these teeth. The longer activation period at the start of space closure was due to an increase in bone density, where tooth movement was expected to be slower as bone remodelling takes longer. The near-end DPT showed completion of space closure without any complications, with satisfactory root parallelism and no signs of root resorption near the DBI lesions (Figure 19). Intraoral photographs taken after space closure was completed (Figure 20) and post-orthodontic treatment (Figure 21) showed satisfactory space closure and finishing.

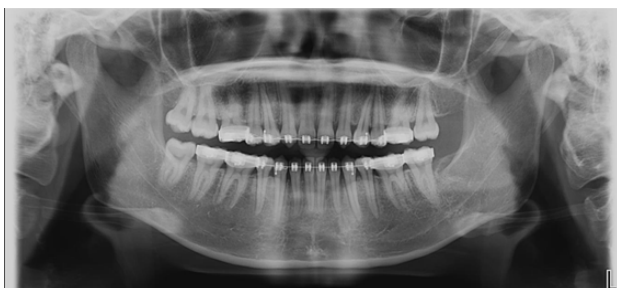

Figure 19: Case 3: DPT after space closure completed

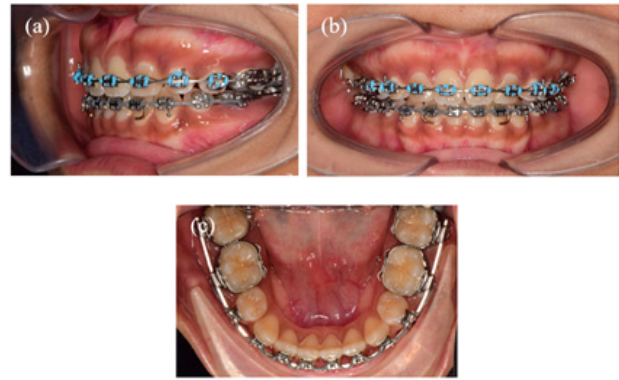


Figure 20: Case 3: Clinical intraoral photographs after space closure completed showing lateral (a), anterior (b) and lingual (c) views

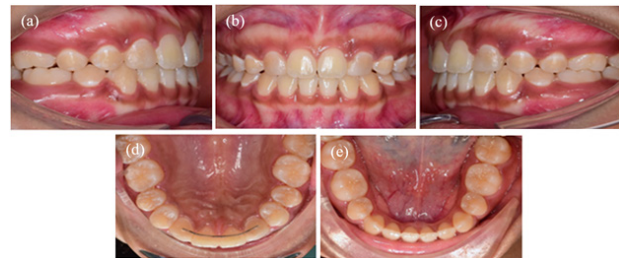

Figure 21: Case 3: Clinical intraoral photographs at debond showing lateral (a and c), anterior (b), palatal (d) and lingual (e) views

Discussion

Orthodontic tooth movement requires bony remodelling, so when a force is applied the surrounding tissues can remodel and permit tooth movement. Accurate diagnosis of any suspected bony abnormality is essential for successful orthodontic outcomes. Radio-opacities in the bone are frequently DBIs; however, the possibility of neoplastic or inflammatory sclerotic lesions in the jaw must be excluded first.

The three cases presented were diagnosed with DBI following clinical, radiographic and in one case histological examination. All three cases presented with DBI in the area of the mandible, which is consistent with other case reports (14, 20). Usually, DBIs are stated to be homogenous (14, 15), however, in Case 1 there was a radiolucent area in the middle of the lesion which was unusual.

One case did not require a CBCT nor a biopsy, as the lamina dura and PDL of the tooth was intact and did not overlap with the lesion. A CBCT was deemed appropriate in one case as the lamina dura and PDL were connected and overlapped the lesion. Once a diagnosis of DBI was confirmed the orthodontic treatment plan involved successful movement of the tooth through the lesion, a similar outcome with another case report with the same presentation (15), although not with fixed appliances.

An author from one case report recommended histological biopsy of DBIs when the size of the lesion increases by 25 percent in 6 months or by 50 percent in one year (6), however, based on our current knowledge there are no approved guidelines. A histological diagnosis is rarely warranted unless there are concerns of inflammatory or neoplastic lesions that can present with signs of expansion of the lesion, such as the tipping and displacement of adjacent teeth, as was shown in Case 2. The biopsy required a surgical intervention with a risk of injury to adjacent neurovascular and dental structures and is therefore only performed when essential to rule out a more sinister diagnosis. Fortunately, in this case the patient suffered no unfavourable sequelae from the surgical intervention.

The size of the presenting lesions were in keeping with the literature (23), although for Case 3 it is unusually large at almost 30 mm. Sinnott and Hodges have reported lesion's measuring 24 mm in diameter (3).

Case 1 and 2 showed the size of the lesion remained largely unchanged throughout treatment. This is consistent with most cases where there is no significant change in size (20). Nonetheless in Case 3, the density appears to reduce with the lesion blended more into the surrounding bone. This has been observed in another case report where it changes over the period of a few years (20). A longitudinal study stated that DBIs can change or remain the same, although it is more likely for the lesions to change appearance in children and adolescents (8). The presented cases are all adults where changes are expected to be minimal; however, one does show the potential of the lesion to change. It is unclear if disruption caused by orthodontic tooth movement results in these changes or they have occurred independently.

Histologically, DBIs represent areas of more compact bone. Animal studies have shown that increased bone density results in slower tooth movement; however, this finding is yet to be confirmed in human studies (24). The authors could not find any reports of a DBI preventing tooth movement; however, there are many case reports claiming a reduced rate of tooth movement through the DBI (3, 4, 20, 25) and difficulty with finishing cases with appropriate tip and torque (3). The presented cases are consistent with one case with a perceived reduced initial rate of space closure when compared with the normal contra-lateral side (Case 3) but have ultimately resulted in successful treatment outcomes with no complications.

It is important to obtain informed consent on increased treatment time when presented with these lesions. Some may argue higher forces are required to stimulate tooth movement in these areas of increased density; however, this may increase the risk of root resorption. Anchorage must be planned carefully in these cases and was reinforced to ensure successful space closure. In a case report involving bone lesions like condensing osteitis, use of a higher force supported by mini-implant were required for space closure (22). It is implied by the case report authors that anchorage reinforcement was needed to apply

additional force to initiate the bone remodelling process. In contrast, we feel that time is a more important factor rather than force magnitude as higher density bone will take longer to remodel. It would still be wise to advise patients of the possibility of the need for anchorage reinforcement if spaces closure is becoming challenging.

In reflection of these cases, it appears safe to precede with tooth movement the region of DBIs, although care must be taken in:

- Ensuring accurate diagnosis.
- Informed consent in particular to include an increased risk of root resorption, slower rate of tooth movement, additional anchorage reinforcements (3).

Once orthodontic treatment is completed, periodic radiographic monitoring is recommended for DBI lesions (25), as there are case reports of DBI increasing in size over time, or a possibility of it being other lesions with similar representation to DBI (3, 4). It is advised that more caution would need to be undertaken in cases with multiple presentations of DBI (3), as there would be a higher likelihood for it to be confused for other similar appearing lesions such as Gardner's Syndrome which can be associated with malignant transformation.

Conclusion

Multidisciplinary discussion is vital in these cases, as well as keeping patients informed with all treatment options and related risks and benefits of each option. With accurate diagnosis and treatment planning, periodical radiographs and sensibility testing, orthodontic treatment can be safely carried out in the cases with DBI lesions.

Acknowledgements

The authors would like to thank the radiographers and supporting staff of Diagnostic Imaging Unit, the supporting students and staff of the Orthodontic Unit, Faculty of Dentistry University Kebangsaan Malaysia for their help in providing radiographic and clinical images for this report.

Financial Support

The authors declare that they have no financial support.

Competing Interests

The authors declare that they have no conflict of interests.

Informed Consent

Informed consent was obtained from all individual participants included in the article.

References

1. Greenspan A, Steiner G, Knutson R. Bone Island (enostosis): Clinical significance and radiologic

- and pathologic correlations. *Skeletal Radiol.* 1991;20(2):85–90.
2. Gerges M, Glard Y, Launay F, Jouve JL, Bollini G, Cottalorda J. Small bone islands: Unusual clinical symptomatology. *Orthopedics.* 2014;37(1):e79–82.
 3. Sinnott PM, Hodges S. An incidental dense bone island: A review of potential medical and orthodontic implications of dense bone islands and case report. *J Orthod.* 2020;47(3):251–6.
 4. Nakano K, Ogawa T, Sobue S, Ooshima T. Dense bone island: Clinical features and possible complications. *Int J Paediatr Dent.* 2002;12(6):433–7.
 5. Ledesma-Montes C, Jiménez-Farfán MD, Hernández-Guerrero JC. Idiopathic osteosclerosis in the maxillomandibular area. *Radiol Medic.* 2019;124(1):27–33.
 6. Mariani GC, Favaretti F, Lamazza L, De Biase A. Dense bone island of the jaw: A case report. *Oral Implantol (Rome).* 2008;1(2):87–90.
 7. Austin BW, Moule AJ. A comparative study of the prevalence of mandibular osteosclerosis in patients of Asiatic and Caucasian origin. *Aust Dent J.* 1984;29(1):36–43.
 8. Petrikowski CG, Peters E. Longitudinal radiographic assessment of dense bone islands of the jaws. *Oral Surg Oral Med Oral Pathol Oral Radiol Endod.* 1997;83(5):627–34.
 9. Ngan H. Growing bone islands. *Clin Radiol.* 1972;23(2):199–201.
 10. Kawai T, Hirakuma H, Murakami S, Fuchihata H. Radiographic investigation of idiopathic osteosclerosis of the jaws in Japanese dental outpatients. *Oral Surg Oral Med Oral Pathol.* 1992;74(2):237–42.
 11. MacDonald-Jankowski DS. Idiopathic osteosclerosis in the jaws of Britons and of the Hong Kong Chinese: Radiology and systematic review. *Dentomaxillofac Radiol.* 1999;28(6):357–63.
 12. Misirlioglu M, Nalcaci R, Adisen MZ, Yilmaz S. The evaluation of idiopathic osteosclerosis on panoramic radiographs with an investigation of lesion's relationship with mandibular canal by using cross-sectional cone-beam computed tomography images. *J Oral Maxillofac Radiol.* 2013;1(2):48–54.
 13. Sisman Y, Ertas ET, Ertas H, Sekerci AE. The frequency and distribution of idiopathic osteosclerosis of the jaw. *Eur J Dent.* 2011;5(4):409–14.
 14. Geist JR, Katz JO. The frequency and distribution of idiopathic osteosclerosis. *Oral Surg Oral Med Oral Pathol.* 1990;69(3):388–93.
 15. Yonetsu K, Yuasa K, Kanda S. Idiopathic osteosclerosis of the jaws: Panoramic radiographic and computed tomographic findings. *Oral Surg Oral Med Oral Pathol Oral Radiol Endod.* 1997;83(4):517–21.
 16. Greenspan A. Bone Island (enostosis): Current concept? A review. *Skeletal Radiol.* 1995;24(2):111–5.
 17. Isaacson K, Thom AR, Atack NE, Horner K, Whaites E. *Orthodontic radiography: Guidelines for the use of radiographs in clinical orthodontics.* 4th Ed. London: British Orthodontic Society. 2015.
 18. Eselman JC. A roentgenographic investigation of enostosis. *Oral Surg Oral Med Oral Pathol.* 1961;14(11):1331–8.
 19. Huang HY, Chiang CP, Kuo YS, Wu YH. Hindrance of tooth eruption and orthodontic tooth movement by focal idiopathic osteosclerosis in the mandible. *J Dent Sci.* 2019;14(3):332–4.
 20. Oshima S, Suzuki J, Yawaka Y. Idiopathic osteosclerosis in the mandible associated with abnormal tooth root formation. *Pediatr Dent J.* 2010;20(1):91–4.
 21. Consolaro A, Paschoal SRB, Ponce JB, Miranda DAO. Florid cemento-osseous dysplasia: A contraindication to orthodontic treatment in compromised areas. *Dental Press J Orthod.* 2018;23(3):26–34.
 22. Baumgaertel S. Socket sclerosis – An obstacle for orthodontic space closure? *Angle Orthod.* 2009;79(4):800–3.
 23. Moshfeghi M, Azimi F, Anvari M. Radiologic assessment and frequency of idiopathic osteosclerosis of jawbones: an interpopulation comparison. *Acta Radiol.* 2014;55(10):1239–44.
 24. Wainwright WM. Faciolingual tooth movement: Its influence on the root and cortical plate. *Am J Orthod.* 1973;64(3):278–302.
 25. Bsoul SA, Alborz S, Terezhalmay GT, Moore WS. Idiopathic osteosclerosis (enostosis, dense bone islands, focal periapical osteopetrosis). *Quintessence Int (Berl).* 2004;35(7):590–1.