

# THE ROLE OF OFFICE-BASED NEEDLE ARTHROSCOPY IN THE DIAGNOSIS OF INTRA-ARTICULAR KNEE SYMPTOMS: A CASE REPORT

**Abdul Gani MS<sup>1</sup>, Hussein KH<sup>2</sup>, Hussein SP<sup>2</sup>, and Mohamed NA<sup>1</sup>.**

<sup>1</sup>Sports Medicine Department, Faculty of Medicine, University of Malaya, 50603 Kuala Lumpur, Malaysia

<sup>2</sup>National Sports Institute of Malaysia, Kuala Lumpur Sports City, Bukit Jalil, 57000 Kuala Lumpur, Malaysia

## **Correspondence:**

Kamarul Hashimy Hussein,  
National Sports Institute of Malaysia,  
Kuala Lumpur Sports City,  
Bukit Jalil, 57000 Kuala Lumpur, Malaysia  
Tel. no: 03-89914880  
Email: drmaruk@gmail.com

## **Abstract**

Anterior cruciate ligament (ACL) tears are serious knee injuries, whether partial or total. ACL injuries are most typically diagnosed in clinic settings using a combination of a detailed history, physical examination and corroborated with an appropriate imaging modality. Magnetic resonance imaging (MRI) is highly sensitive for identifying intra-articular knee pathology. This combination has been demonstrated to be effective and non-invasive in diagnosing ACL injury. The reliability of MRI for diagnostic purposes, on the other hand, is not always ideal. This might be due to various factors, including low-quality MRI magnets, post-surgical tissue changes, metallic artifacts, patient movement during the procedure, and static rather than dynamic structural evaluation. Nevertheless, office-based diagnostic arthroscopy offers an alternative to imaging modalities by allowing clinicians to visualize large joints safely, with painless, high-quality images, and time-efficient approaches. Furthermore, the risk of major and minor complications of office-based diagnostic arthroscopy is comparable to or lower than any standard office-based injection. This is the first office-based needle arthroscopy (OBNA) performed in Malaysia to evaluate intra-articular knee symptoms. Thus, we aim to understand and overview OBNA to identify intra-articular knee pathology by reporting this case report.

**Keywords:** Intra-articular Knee, ACL Tears, Arthroscopy, Office-based

## **Introduction**

ACL tears, whether partial or total, are serious knee injuries which common injury that occurs in individuals active primarily in sports and recreational activities (1). The total incidence rate ranges from 30 to 80 per 100,000 person-years in the general population. This corresponds to more than 120,000 to 200,000 ACL repairs in the United States alone per year (2). ACL injuries are most typically diagnosed in the clinic settings using a combination of a detailed history, physical examination and corroborated with an appropriate imaging modality. MRI is currently the highly sensitive imaging modality for diagnosing intra-articular knee disease (3). This combination has been shown to be effective and non-invasive in assessing ACL injury.

The reliability of MRI for diagnostic purposes, on the other hand, is not always ideal. This might be due to various factors, including low-quality MRI magnets, post-surgical tissue changes, metallic artifacts, patient movement during procedure, and static rather than dynamic structural

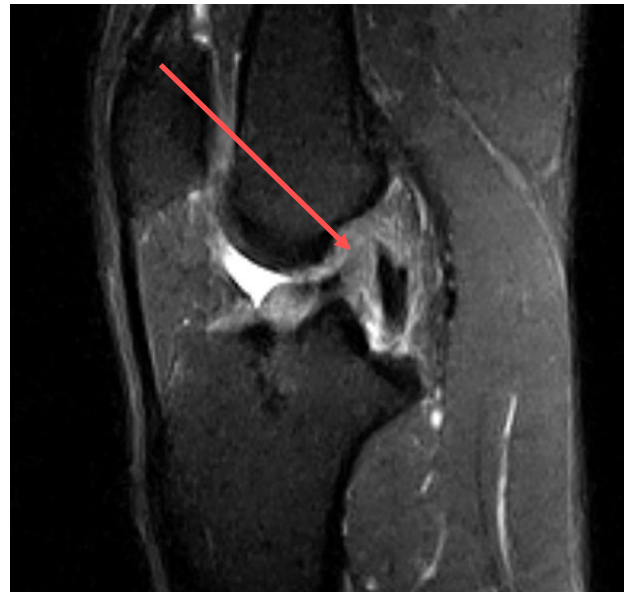evaluation. Furthermore, previous systematic studies found that when identifying complete anterior cruciate ligament injuries, MRI has a sensitivity of 94.5%, a specificity of 95.3%. When assessing partial or chronic tears, these rates are even lower (4). Even though it is very reliable, advanced imaging misdiagnoses ACL pathology in one in 14 individuals. When evaluating for meniscal pathology, the accuracy reduces even further (88% lateral meniscus, 86% medial meniscus) (5). A previous study showed that MRI missed meniscal pathology in one out of every 10 cases and identified pathology in one out of every five patients when it does not exist (6). However, these diagnostic limitations do not account for individuals who are unable to undergo an MRI for a variety of reasons. Claustrophobia, body shape, cost, metal in the body, and MRI accessibility are all considered factors. In these circumstances, obtaining an accurate diagnosis can be difficult for both the clinician and the patient. As a result, many clinicians have shifted to different imaging modalities to understand their patients' pathology better.

### Case History

This 29-year-old male attended to our clinic with a primary complaint of left knee pain. He had a history of injury while playing football three days ago. During that time, he had been tackled from behind, valgus position with foot planted. The left knee was twisted with the tibia internally rotated during the incident, and a pop sound was heard. He could not walk after the injury and had to be assisted off the field. He reported acute left knee pain associated with gradual knee swelling. He did apply ice compression and a knee compression band at home to reduce the swelling. Due to pain, he could not fully bend his knee, but he could still walk unassisted the next day. His medical history shows that he had a left knee ACL reconstruction six years ago due to a sports-related injury. According to his medical records, he underwent bone-patellar tendon-bone autograft ACL reconstruction. He stated that after his reconstruction surgery, he was able to return to a high level of functional activity, including football. On the third post-injury day, he observed that bending the knee aggravated the pain once the swelling had reduced. Other than that, he denies catching and locking symptoms. Furthermore, he did not experience instability because he did not attempt a pivoting action at the time.

### Physical Examination

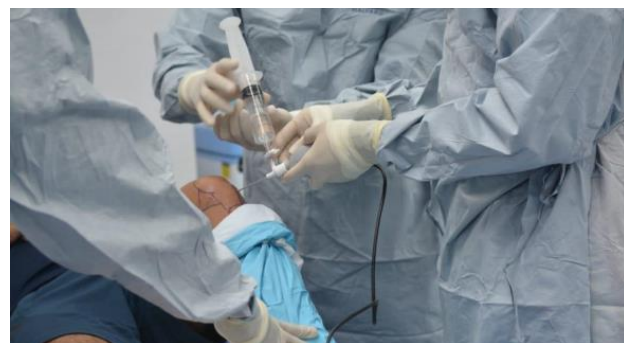There was minimal effusion and no noticeable deformity or erythema on physical examination. The range of motion was restricted to the contralateral knee, with 5° extension deficit and 120° flexion. On palpation, there was tenderness along the medial joint line, lateral femoral condyle, and lateral tibial condyle. An anterior drawer test score of 2+, Lachman score of 2+, and positive apprehension with pivot shift testing were obtained from stability tests. There was no varus or valgus gapping on collateral ligament testing, and McMurry's sign was negative. The sensation, perfusion, and reflexes were symmetric and equal on both lower limbs. Motor testing shows that the quadriceps and hamstrings have a strength of 5/5. Because his radiographs were normal, the patient was scheduled for an MRI of his left knee (Figure 1). The radiologist and orthopaedic surgeon agreed that the patient had a high degree partial ACL injury with an ACL bony contusion pattern. The meniscus was intact, and the remainder of the knee joint was unremarkable. Ten days following his injury, the patient was offered an office-based diagnostic needle arthroscopy, which he agreed due to his limitation of movement and to identify whether there was any pathology causing the restriction. The OBNA procedure was performed for the first time in Malaysia on December 16<sup>th</sup>, 2021, at the National Sports Institute clinic.



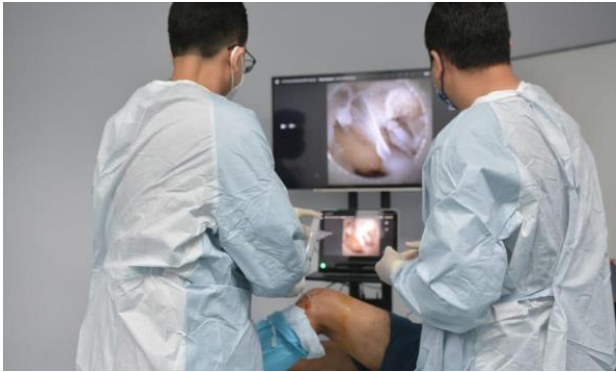**Figure 1:** A T2 sagittal image showing an ACL graft laxity with high signal intensity and thickening associated with anterior tibial translation suspicious of a partial tear of the ACL graft

### Technique for Procedure

After explaining the benefits and disadvantages of an OBNA under local anaesthesia vs. an operating room (OR) arthroscopic assessment under anaesthesia, the treating clinician obtained informed consent from the patient. The patient was next positioned sitting up, and marked knees flexed to 90° off the bed's edge (Figure 2). After a standard sterile betadine and alcohol prep, the patient was anaesthetized in a lateral portal position with a 2 cc of plain lignocaine injected to the skin and 10 cc of plain bupivacaine mixed with 10 cc plain lignocaine injected into the joint. The skin and joint capsule needed to be numbed in a circular fashion. The procedure began once the skin was numbed. The intercondylar notches, as well as the medial and lateral compartments of the knee, were evaluated (Figure 3).

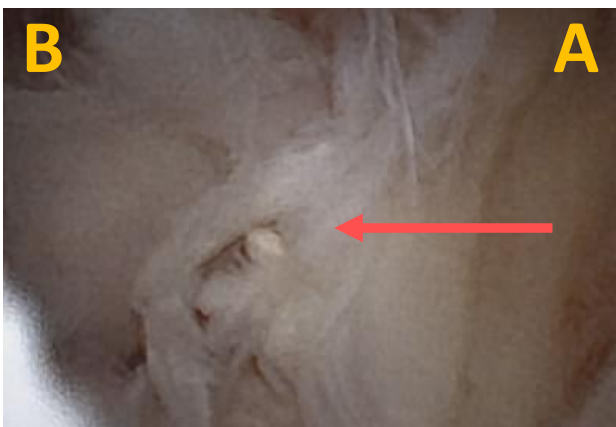

**Figure 2:** Insertion of the probe into the lateral portal of the left knee with the patient is lying on supine with knee flexed 90°. The syringe connected to the probe and stopcock is open and ready to distend the capsule

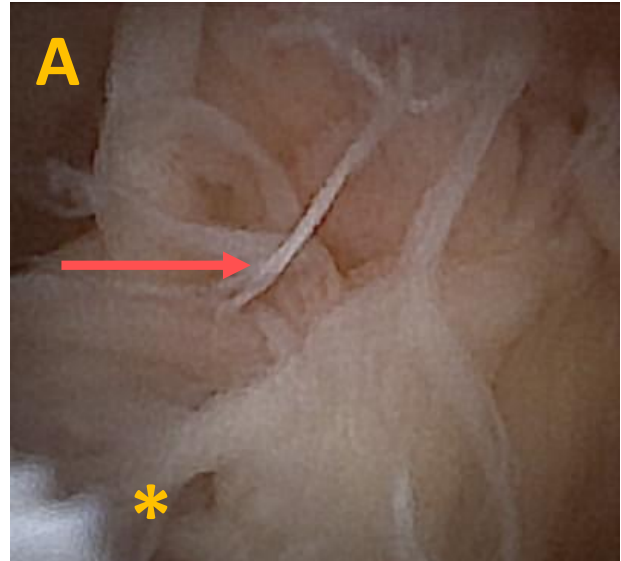


**Figure 3:** The operator (clinician) can directly visualise the image on the screen tablet throughout a procedure similar to OR arthroscopy

A valgus force was given to the patient’s knee to access the medial compartment, while the physician’s assistant provided a supporting force to the patient’s thigh. This dynamic leg movement is similar to that seen in standard OR arthroscopy. The lateral compartment was similarly accessed by gently placing the patient’s knee in the 90° flexion. Following the evaluation of the medial and lateral compartments, the ACL was evaluated. The ACL is seen in Figure 4, with the knee flexed to 90°. The image shows that fraying of ACL fibres with thinning of the ligament. Figure 5 shows the insufficiency of the ACL graft, which is peeling away from the intercondylar notch. The posterior cruciate ligament (PCL) showed vascularity but no laxity. The total procedure takes approximately 30 minutes and the patient had no complications or complaints throughout the procedure and post-procedure observation. He was then discharged with five days of oral antibiotics and oral analgesics. The International Knee Documentation Committee (IKDC) score was obtained before the procedure, 24 hours post-procedure, and one week after the OBNA. The results showed that IKDC had a total score of 57.5%, 58.6%, and 72.4%, respectively.



**Figure 4:** Viewed from the lateral portal with the knee flexed to 90°, there is fraying of ACL fibres with thinning of the ligament. (A: Lateral femoral condyle, B: Medial femoral condyle, Arrow: ACL remnant)



**Figure 5:** Viewed from the lateral portal, the ACL graft demonstrates incompetency as it peels off the intercondylar notch. (A: Lateral femoral condyle, Asterisk: Intercondylar notch, Arrow: ACL remnant)

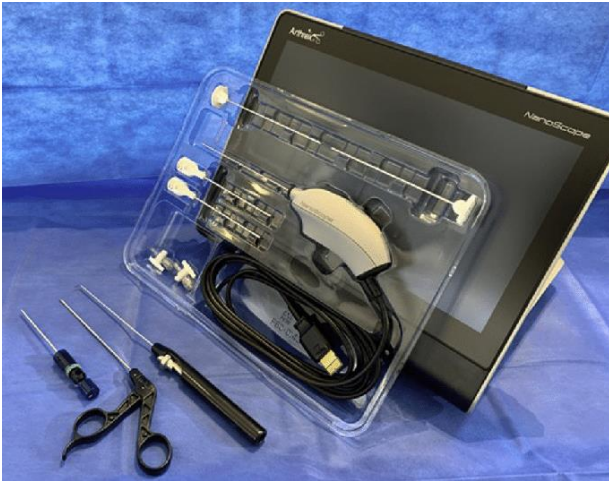**Discussion**

**Alternative Imaging Approaches**

By allowing clinicians to visualize large joints safely, painlessly, and time-efficient, office-based diagnostic arthroscopy offers an alternative to imaging modalities. In addition, it has been demonstrated that it is a quickly evolving technology that can deliver equivalent or superior diagnostic accuracy to MRI (7). The ability to provide real-time dynamic visualization of the patient’s anatomy aids clinicians in making more accurate assessments.

As a result, the timeframe between injury, diagnosis, and recovery may be shortened. Furthermore, current research indicates that the risk of major and minor complications is equivalent to or lower than that of any standard office-based injection (8). Intra-articular pathology determines the indications for usage. ACL tears, meniscal tears, loose bodies, second look evaluations of cartilage procedure, and helping in decision-making for patients facing possible unicompartmental vs. total knee replacements are among the most frequently diagnosed pathologies for the knee. Needle arthroscopy with a nano-arthroscope is a technique that allows for direct high-quality intra-articular viewing without the use of general anaesthesia and can be performed in the office or the OR (Figure 6). The handpiece is a disposable sterile packaging that connects to a tablet device (Figure 7). It has a 120° field of vision and generates a 0° picture when viewed instead of the conventional arthroscopic 30° view. The 14-gauge outer sheath retracts as the handpiece is introduced into the joint, allowing the optics and light source to be deployed. The connection between the handpiece and the tablet allows capturing both static images and video footage. If

the surgeon or patient desires, these images can be saved on a storage device.



**Figure 6:** The needle arthroscopy setup, which includes an arthroscope with monitor, power cord, trocars with sheaths, inflow ports, and other equipment (NanoScope; Arthrex)



**Figure 7:** A close-up of the needle arthroscopy with a retractable outer sheath, 14-gauge, 95 mm length. This disposable needle arthroscopy has a 120° field of view and a 0° image

In our case, needle arthroscopy was used to identify symptomatic patients with occult imaging abnormalities. Although MRI is a practical and minimally invasive diagnostic tool, it is restricted by anatomic variations, artifacts, and pathological misinterpretation. Furthermore, a static MRI cannot match the improvement reported with a dynamic knee evaluation. For intra-articular knee pathologies, surgical arthroscopy remains the gold standard (9). Particularly in this case as discussed, OBNA can determine whether there is particular articular cartilage lesion or scarring from earlier trauma or surgery that causes the pain symptom since only low-field MRI

investigation was performed. It may also be beneficial for patient with intra-articular pathology who are unable to have an MRI due to medical reasons or claustrophobia. This would give the clinician with a more convenient and time-efficient technique of visualising the previous repair without requiring the patient to return to the OR for a standard diagnostic arthroscopy. OBNA can also aid in the assessment of the knee joint prior to the use of an allograft, such as an osteochondral or meniscal allograft (10). A diagnostic arthroscopy is frequently necessary prior to procedure authorization in these cases. Furthermore, recent research has demonstrated that the technique's complication risk is comparable to or lower than that seen with standard office-based injections (8). Standard surgical, diagnostic arthroscopy in the OR might require patients to take off work and risk them to anaesthetic side effects. Furthermore, if the patient is required to return for definitive surgical intervention at a later date due to unexpected results, these surgical risks may be exacerbated. The OBNA has the benefit of being able to be conducted in an outpatient setting with on-the-spot findings, allowing for an immediate discussion of treatment options with the patient. Moreover, the procedure took around 30 minutes from the injection of local anaesthetic until the procedure was completed, as compared to a minimum of one hour plus additional time for post-anaesthesia monitoring in patients undergoing general or regional anaesthesia. The diagnostic gap between MRI and the surgical risks of OR diagnostic arthroscopy can be bridged using OBNA.

Our findings support current research that reported OBNA as highly useful as MRI in diagnosing intra-articular knee disease and the needle arthroscopy is similar to standard arthroscopy as gold standard for diagnosing intra-articular knee pathology. In a study of 106 patients with intra-articular knee pathology, Deirmengian et al. found that needle arthroscopy was more sensitive and specific than MRI in detecting *meniscal* tears (11). Zhang K et al. reported that needle arthroscopy was equal to surgical arthroscopy in OR and superior to MRI for identifying intra-articular knee pathology in systematic studies (12). Furthermore, Mc Millan et al. and Voigt et al. observed a considerable cost-benefit of using office-based arthroscopy over MRI because of enhanced diagnostic accuracy (6, 12). Finally, we show that OBNA may be used as a diagnostic tool in symptomatic patients when consistent imaging results. However, there are certain limits to office-based arthroscopy. It is essential to highlight appropriate patient selection because this is a completely local anaesthetic procedure that must be considered in patients who exhibit signs of needle phobia. The visualization is not as straightforward as it would be with a proper surgical, diagnostic arthroscopy in OR due to the smaller size of the needle. Furthermore, suppose the patient has hemarthrosis or formed during the OBNA procedure, the visualization might be significantly limited since the clinician cannot circulate fluid into the knee to clear it out. Scar tissue can also limit the small-bore needle's excursion in patients who previously had surgery.

## Conclusion

As a result, OBNA offers high-quality imaging, accurate and safe modality approach for identifying missing or hidden intra-articular knee pathology. More study is needed, however, to identify the prevalence of missing injuries and the feasibility of needle arthroscopy in shedding light on this issue. Although OBNA is not always necessary, its use in selected cases can significantly improve and expedite patient care while minimising the cost and morbidity of an unnecessary surgery. Furthermore, OBNA provides clinicians with additional diagnostic tools that may be used in a variety of clinical settings.

## Competing interests

The authors declare that there is no conflict of interest.

## Financial support

There is no financial support received for the study.

## Informed consent

Informed consent was obtained from the patient for inclusion in this report. Research and ethics committee approval for case reports is not a requirement according to Medical Research and Ethics Committee and Institute for Clinical Research Malaysia.

## References

1. Kalimuthu M. Muscle bulk, strength and proprioceptive difference between anterior cruciate ligament deficient and normal knee. *J Health Trans Med.* 2017;20(1):1-5.
2. Raines BT, Naclerio E, Sherman SL. Management of anterior cruciate ligament injury: What's in and what's out? *Indian J Ortho.* 2017;51(5):563-75.
3. Cellár R, Sokol D, Lacko M, Štolfa Š, Gharaibeh A, Vaško G. Magnetic resonance imaging in the diagnosis of intra-articular lesions of the knee. *Acta Chir Orthop Traumatol.* 2012;79:249-54.
4. Smith TO, Lewis M, Song F, Toms AP, Donell ST, Hing CB. The diagnostic accuracy of anterior cruciate ligament rupture using magnetic resonance imaging: A meta-analysis. *Eur J Orthop Surg Traumatol.* 2012;22(4):315-26.
5. Esmaili Jah AA, Keyhani S, Zarei R, Moghaddam AK. Accuracy of MRI in comparison with clinical and arthroscopic findings in ligamentous and meniscal injuries of the knee. *Acta Orthop Belg.* 2005;71(2):189-96.
6. Crawford R, Walley G, Bridgman S, Maffulli N. Magnetic resonance imaging versus arthroscopy in the diagnosis of knee pathology, concentrating on meniscal lesions and ACL tears: A systematic review. *Br Med Bull.* 2007;84:5-23.
7. McMillan S, Saini S, Alyea E, Ford E. Office-based needle arthroscopy: A standardized diagnostic approach to the knee. *Arthrosc Tech.* 2017;6(4):e1119-e24.
8. McMillan S, Chhabra A, Hassebrock JD, Ford E, Amin NH. Risks and Complications associated with intra-articular arthroscopy of the knee and shoulder in an office setting. *Orthop J Sports Med.* 2019;7(9):2325967119869846.
9. Patel KA, Hartigan DE, Makovicka JL, Dulle DL, Chhabra A. diagnostic evaluation of the knee in the office setting using small-bore needle arthroscopy. *Arthrosc Tech.* 2017;7(1):e17-e21.
10. Shelbourne KD, Nitz P. Accelerated rehabilitation after anterior cruciate ligament reconstruction. *Am J Sports Med.* 1990;18(3):292-9.
11. Deirmengian CA, Dines JS, Vernace JV, Schwartz MS, Creighton RA, Gladstone JN. Use of a Small-bore needle arthroscope to diagnose intra-articular knee pathology: comparison with magnetic resonance imaging. *Am J Orthop.* 2018;47(2).
12. Zhang K, Crum RJ, Samuelsson K, Cadet E, Ayeni OR, Sa de D. In-office needle arthroscopy: a systematic review of indications and clinical utility. *Arthrosc.* 2019;35(9):2709-21.
13. Voigt JD, Mosier M, Huber B. In-office diagnostic arthroscopy for knee and shoulder intra-articular injuries its potential impact on cost savings in the United States. *BMC Health Serv Res.* 2014;14:203.