

UNEXPLAINED NEUROLOGICAL DEFICIT WITH IMPAIRED VASCULAR PERFUSION: A MISSED TELL-TALE SIGN OF AORTIC DISSECTION PRESENTING IN A DISTRICT HOSPITAL

Ang SP¹, Abdullah AA^{1,2}, Nor J^{1,2}, and Liu YS³.

¹Department of Emergency Medicine, School of Medical Sciences, Universiti Sains Malaysia, Kubang Kerian, Kelantan, Malaysia

²Emergency Department, Hospital Universiti Sains Malaysia, Kubang Kerian, Kelantan, Malaysia

³Emergency Department, Hospital Seberang Jaya, Perai, Pulau Pinang, Malaysia

Correspondence:

Ang Sheau Phing,
Department of Emergency Medicine,
School of Medical Sciences,
Universiti Sains Malaysia,
16150 Kubang Kerian,
Kelantan, Malaysia.
Email: sheauphing28@gmail.com

Abstract

Acute aortic dissection can present with a diverse range of clinical signs and symptoms. It is a condition with high morbidity and mortality that could be missed without a high index of suspicion. This case examines a 45-year-old gentleman who presented to a district hospital with hemodynamically unstable, acute right-sided body weakness associated with a fall the day prior. He also reported frank haematuria, with suprapubic, pelvic, and right thigh pain for the past three days. A preliminary diagnosis of cerebral vascular accident with a need to rule out intracranial bleeding was made, and he was arranged for an urgent computed tomography brain scan at a secondary hospital. Unfortunately, he eventually succumbed to cardiac tamponade secondary to aortic dissection.

This case highlights the challenge clinicians face in identifying a vascular emergency that disguises with a history of trauma. This challenge is further amplified in hospital settings with scarce resources and expertise. Therefore, a thorough history taking, a focused physical examination, and a high index of suspicion are crucial for making an accurate diagnosis.

Keywords: Aortic Dissection, Neurologic Deficit, Vascular, Emergency

Introduction

Aortic dissection is characterised by the separation of the intimal layer within the aortic wall and leads to the spread of dissection secondary to blood entering the intima-media space. It carries a high risk of morbidity and mortality without early diagnosis and prompt intervention. The incidence of acute aortic dissection is estimated to range from 2.6 to 3.5 per 100,000 person-years (1).

Aortic dissection typically presents with severe and catastrophic symptoms, with the most common onset symptoms being chest pain and hemodynamic instability (2). However, patients may also present with neurological signs, symptoms of cerebrovascular accident, altered mental status and peripheral nerve ischaemia. In addition, the management of acute aortic dissection can be challenging, especially in settings where appropriate

facilities and specialties for immediate intervention are lacking. Here, we report a case of aortic dissection presented with body weakness and hemodynamic instability in a district hospital without Computed Tomography (CT) modality or surgical expertise.

Case presentation

A 45-year-old Chinese gentleman, an active smoker with no known comorbidities, presented with a 1-hour history of right-sided body weakness, associated with frank haematuria, with suprapubic, pelvic, and right thigh pain for the past three days. Upon further questioning, he reported slipping and falling backward the day before, with his head landing on the toilet floor. There was no direct impact on his chest or abdomen. Post-trauma, he did not experience any altered consciousness or symptoms of head

injury and was still able to ambulate. He denied having a fever, gastrointestinal loss, chest pain, or abdominal pain.

Upon arrival at the Emergency Department, he was alert despite being hypotensive [blood pressure (BP): 85/55 mmHg], tachycardic [pulse rate (PR): 120 beats per minute], mildly tachypnoeic [respiratory rate (RR): 20 breaths per minute], and hypoxic (SpO₂: 93% under ambient air). He was afebrile (temperature: 36.9°C) with good peripheral perfusion. Bruising was observed over his right lower abdomen, extending to the right thigh, with mild tenderness upon palpation. Neurological examination of four limbs revealed hypotonic in the right lower limb, muscle strength of 1/5 in the right lower limb and 4/5 in the right upper limb. Reflexes in all four limbs were normal. His right lower limb appeared paler and colder compared to the left side, with feeble pulses over the right femoral, popliteal, posterior tibial, and dorsalis pedis arteries. A bedside Focus Assessment with Sonography in Trauma (FAST) scan revealed no intra-abdominal free fluid.

The initial blood panel revealed leucocytosis (White Blood Cell count: $13.5 \times 10^3/\mu\text{L}$), a slightly elevated Activated

Partial Thromboplastin Time of 34.5s (Prothrombin Time: 11.9s, International Normalised Ratio: 1.14), and mildly elevated creatinine levels (150 $\mu\text{mol/L}$, urea: 4.10 mmol/L), hypermagnesemia (Mg: 1.19 mmol/L), with normal levels of haemoglobin, platelets, sodium, and calcium (haemoglobin: 15.5g/dL, platelets: $157 \times 10^3/\mu\text{L}$, sodium: 136 mmol/L, and corrected calcium: 2.2 mmol/L). Serum potassium, phosphate, cardiac enzymes, and a full liver function tests were sent but were unable to be processed due to a haemolysed sample.

The venous blood gas analysis revealed metabolic acidosis (pH: 7.25, PvO₂: 43 mmHg, PvCO₂: 29 mmHg, SvO₂: 77%, HCO₃: 14 mmol/L, Base excess: -14.7). His blood glucose was 14.5 mmol/L, with serum ketones at 0.2 mmol/L. Urinalysis revealed 3+ occult blood and 2+ protein. An electrocardiogram (ECG) displayed widespread ST segment depression, as illustrated in Figure 1 and 2. Additionally, a portable X-ray scan showed no obvious fractures in the chest, pelvis, or right femur.

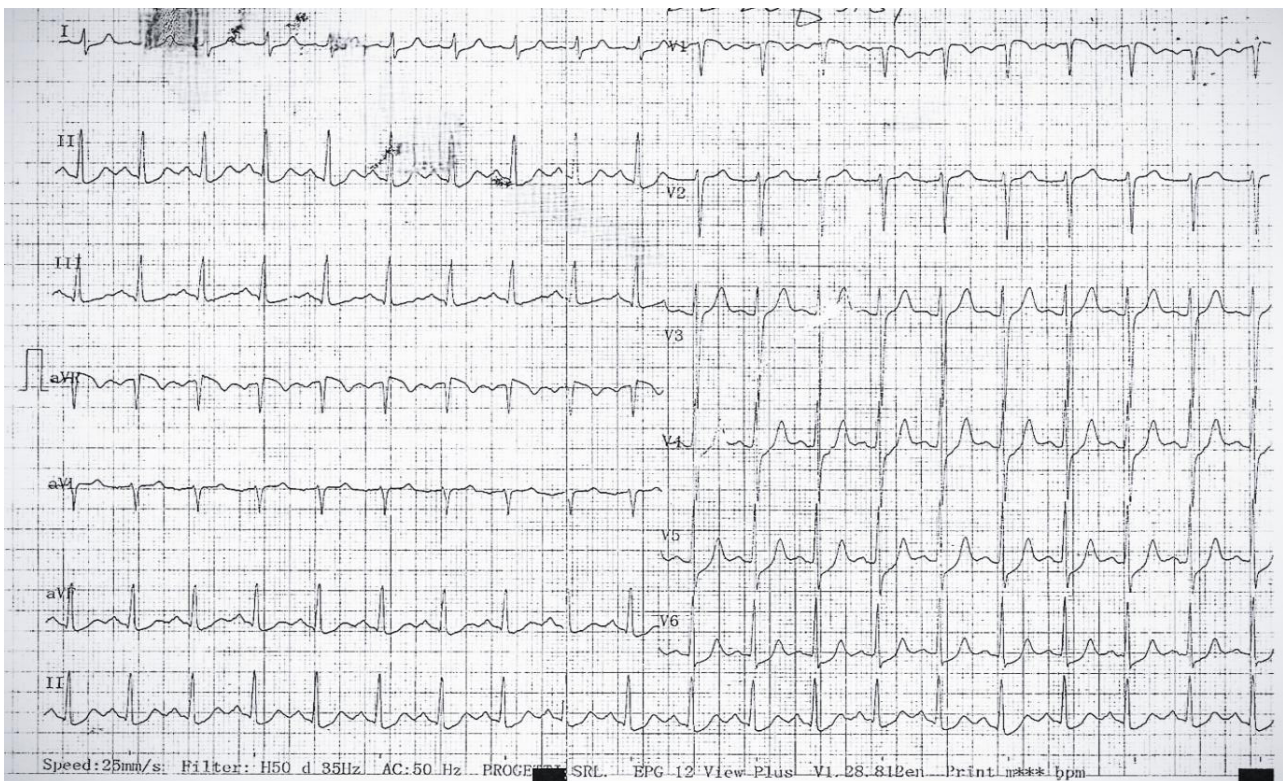


Figure 1: ECG showing widespread ST segment depression.

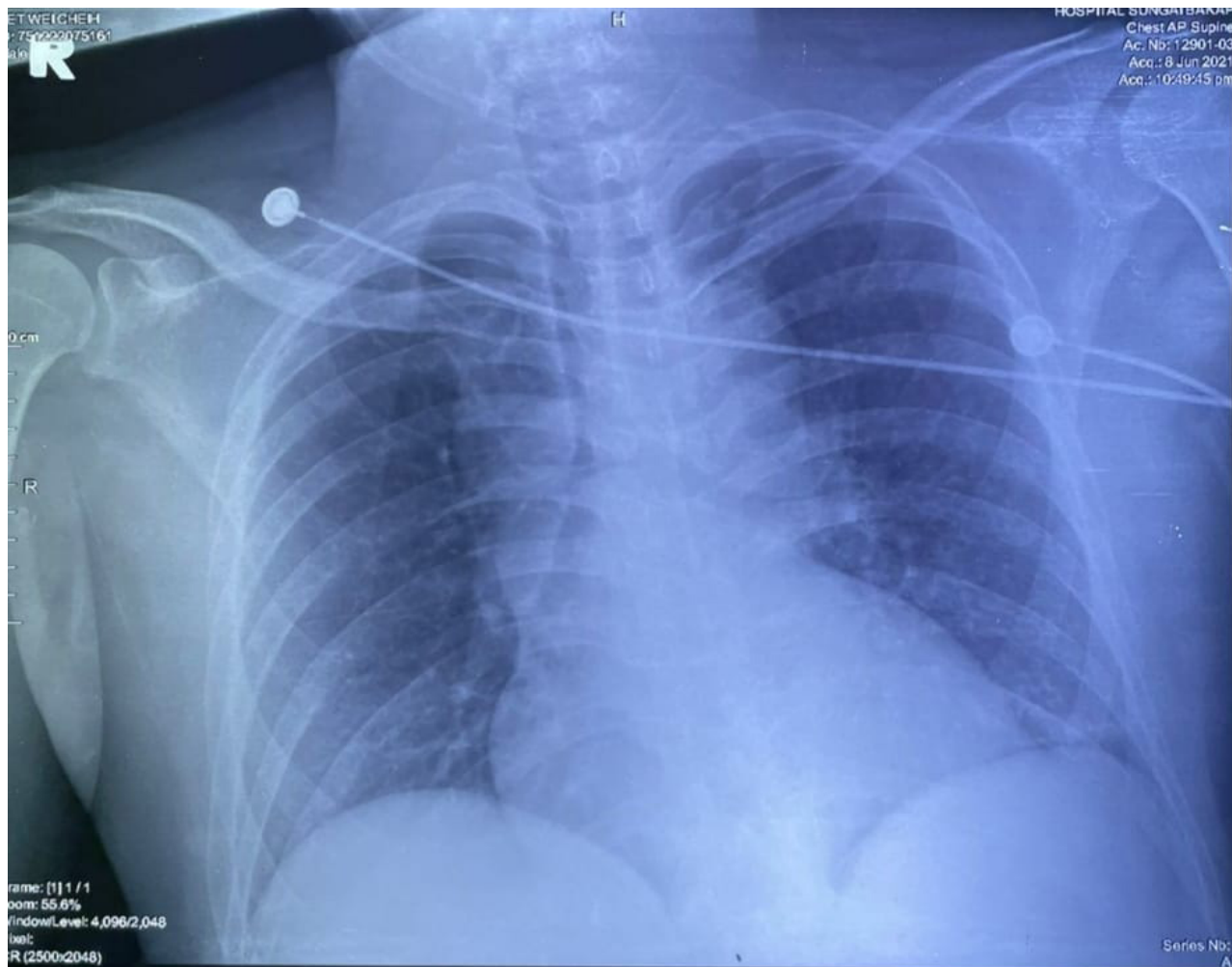


Figure 2: Chest X-ray (anteroposterior view, rotated film) showing a widened mediastinum measuring approximately 11 cm.

A preliminary working diagnosis of cerebral vascular accident with a need to rule out intracranial bleeding, and haematuria requiring investigation to rule out pelvic fracture and vascular injury, was made. He was arranged for an urgent CT brain scan at another secondary hospital as a CT scan was not available at the district hospital.

He received fluid resuscitation with a total of three pints of normal saline before being started on IVI noradrenaline at 0.2 mcg/kg/min due to persistent hypotension (BP ranging from 85-95/53-63 mmHg) and tachycardia (PR: 109-123). In addition, he was placed on face mask oxygen (FMO₂) at 5L/min for his hypoxia (SpO₂: 96-97% under FMO₂ 5L/min) and tachypnoea (RR: 24 breaths per minute). He was also administered intravenous Tramadol 50 mg for pain, and a bladder catheter was inserted to monitor urine output.

The blood tests repeated approximately two hours later revealed a drop in haemoglobin level to 13.9 g/dL and platelets to 122x10³/μL. Arterial blood gas analysis under FMO₂ 5L/min revealed compensated metabolic acidosis (pH: 7.32, PaO₂: 135 mmHg, PaCO₂: 22 mmHg, SaO₂: 99%, HCO₃: 15 mmol/L, Base excess: -14.8). Cardiac enzymes

indicated elevated AST and LDH levels (AST: 171U/L, CK: 147U/L, LDH: 339U/L).

After approximately 2.5 hours in the hospital, he experienced a drop in his Glasgow Coma Scale to E4 (blank stare) V1M1, with no palpable pulse. The cardiac monitor displayed pulseless electrical activity. He was subsequently intubated and resuscitated as per Advanced Life Support protocol. There was no shockable rhythm observed throughout the resuscitation. He eventually succumbed.

A post-mortem examination was performed and revealed minimal haematoma over the subgaleal region, with no evidence of intracranial bleeding, cerebral oedema, or skull fracture. Cardiac tamponade was identified, with 450 ml of fluid and 22g of clots encapsulating the heart. A dense haematoma was noted over the ascending aorta. The coronary arteries were mildly occluded by atheroma, with no thrombus present. Additionally, the caecum and ascending colon were gangrenous. The cause of death was concluded as cardiac tamponade secondary to aortic dissection.

Discussion

Acute aortic dissection is a potentially lethal condition characterised by the separation of the aortic wall layers into true and false lumens, which may lead to serious complications, including aortic rupture, myocardial ischaemia, hypotension/shock, end-organ ischaemia, and death (3). According to a study conducted by Pape et al. (4), several risk factors are associated with aortic dissection, with hypertension being the most common (76.6%), followed by atherosclerosis (26.5%), previous cardiac surgery (16.1%), known aortic aneurysm (15.5%), and iatrogenic (2.8%). The risks of having aortic dissection in our patient were most likely atherosclerosis and active smoking.

The sudden onset of severe chest or back pain is the most frequent symptom of aortic dissection (5). Nonetheless, there were reported cases of aortic dissection with neurological symptoms such as painless unilateral upper limb numbness and weakness (6, 7), acute paraplegia (8-10), and paraparesis (11, 12). Gaul et al. (13) reported that transient or permanent neurological symptoms occur at the onset of aortic dissection in 17–40% of patients. These symptoms are often dramatic, might mask the underlying condition, and may lead to difficulty and delay in diagnosis, especially in pain-free dissections (which occur in 5–15%) with predominant neurological symptoms. Hence, clinicians should maintain a high index of suspicion for the possibility of aortic dissection in patients presenting with neurological deficits, as aortic dissection may have various presentations with potentially fatal outcomes.

Our patient presented with acute onset right-sided body weakness, frank haematuria, with suprapubic, pelvic, and right thigh pain, complicated with a preceding history of fall which warranted consideration of both acute stroke and traumatic causes. There were several challenges encountered in managing this patient, which include the importance of ruling out acute ischaemic stroke, considering the time-sensitive potential benefits of thrombolytic therapy, the masquerading effect of trauma history, and limitations in resources and expertise available at the district hospital. Hence, clinicians must excel in history taking and physical examination, and maintain a high index of suspicion. Other than that, bedside Point of Care Ultrasound (POCUS) would be beneficial in early identification of pericardial tamponade, therefore, allowing for early intervention.

Furthermore, acute aortic dissection can propagate in an antegrade or retrograde fashion, involve side branches, and lead to complications such as malperfusion syndrome due to the dynamic or static obstruction (from coronary to iliac arteries), tamponade, or aortic insufficiency (14). The rapid lethality of this condition often involving severe physiologic derangements from complications such as pericardial tamponade, myocardial infarction, malperfusion syndromes affecting the brain, kidney, spinal cord and/or gut, or frank exsanguination from aortic rupture have magnified the importance of early diagnosis

and treatment which are critical for survival (3). In our case, the patient was already in shock upon arrival, exhibiting haemodynamic instability from cardiac tamponade and malperfusion syndrome, which explained the gangrenous caecum and ascending colon, along with acute limb ischaemia, as evidenced by the paler, colder right lower limb with feeble pulses.

In its natural cause, without treatment, acute type A aortic dissection reportedly has an initial mortality rate of about 1% per hour, with 50% mortality by the third day and almost 80% by the end of the second week (15). However, local data in Malaysia is still unavailable and statistics from Western countries may not accurately reflect our local disease pattern. Moreover, managing acute aortic dissection requires multidisciplinary expertise, which is unfortunately not available in our district hospital.

In a nutshell, acute aortic dissection has various presentations and can lead to rapid deterioration with severe complications without early diagnosis and prompt intervention.

Conclusion

Early diagnosis and prompt intervention can be challenging in managing patients with acute aortic dissection, especially in district hospitals with limited facilities and expertise. A history of trauma may obscure the presentation of this condition. Therefore, clinicians should maintain a high index of suspicion for aortic dissection in patients presenting with haemodynamically unstable neurological deficits, as these symptoms may indicate a more insidious underlying condition rather than an isolated neurological disorder. Additionally, POCUS should be adopted in resuscitation, if feasible.

Informed Consent

The patient had been informed and verbal consent obtained upon presentation for the publication of his clinical information.

Competing interests

The authors declare that they have no competing interests.

Financial support

No funding was received for this work.

References

1. Clouse WD, Hallett JW Jr, Schaff HV, Spittell PC, Rowland CM, Ilstrup DM, *et al.* Acute aortic dissection: population-based incidence compared with degenerative aortic aneurysm rupture. *Mayo Clin Proc.* 2004; 79:176–180
2. Mowafy A, Rath P, Eladly A, Omran A. An Atypical Presentation of Severe Dissecting Aortic Aneurysm: A Case Report and Literature Review. *Cureus.* 2021 June; 13(6):e15752.

3. T.T.Tsai, S.Trimarchi, C.A.Nienaber. Acute Aortic Dissection: Perspectives from the International Registry of Acute Aortic Dissection (IRAD). *European Journal of Vascular and Endovascular Surgery*. February 2009; 37(2):149-159.
4. Pape LA, Awais M, Woznicki EM, Suzuki T, Trimarchi S, Evangelista A, *et al*. Presentation, diagnosis, and outcomes of acute aortic dissection: 17-year trends from the international registry of acute aortic dissection. *J Am Coll Cardiol*. 2015; 66:350–358.
5. Evangelista A, Isselbacher EM, Bossone E, Gleason TG, Eusanio MD, Sechtem U, *et al*. Insights from the International Registry of Acute Aortic Dissection: A 20-Year Experience of Collaborative Clinical Research. *Circulation*. 2018; 137:1846–1860.
6. Koushima R, Kikuchi Y, Sakurada T, Kusajima K. A case of painless Stanford type A acute aortic dissection complicating acute occlusion of the right subclavian artery. *Kyobu Geka*. Japanese. 1998 Mar; 51(3):226-30.
7. Liu KT, Chan HM, Lin TJ. Painless aortic dissection with initial symptom of right upper extremity weakness: a case report. *Kaohsiung J Med Sci*. 2007 Jan; 23(1):45-9.
8. Donovan EM, Seidel GK, Cohen A. Painless aortic dissection presenting as high paraplegia: a case report. *Arch Phys Med Rehabil*. 2000 Oct; 81(10):1436-8.
9. Rabadi MH. Acute aortic dissection presenting as painless paraplegia. *J Gen Intern Med*. 2014 Feb; 29(2):410-411.
10. Joo JB, Cummings AJ. Acute thoracoabdominal aortic dissection presenting as painless, transient paralysis of the lower extremities: a case report. *J Emerg Med*. 2000 Nov; 19(4):333-7.
11. Hsu YC, Lin CC. Paraparesis as the major initial presentation of aortic dissection: report of four cases. *Acta Neurol Taiwan*. 2004; 13(4):192–7
12. Waltimo O, Karli P. Aortic dissection and Paraparesis. *Eur Neurol*. 1980; 19:254–7.
13. Gaul, C., Dietrich, W., Erbguth, F. J. Neurological Symptoms in Aortic Dissection: A Challenge for Neurologists. *Cerebrovascular Diseases*. 2008; 26(1):1–8.
14. Nienaber CA, Eagle KA. Aortic Dissection: New Frontiers in Diagnosis and Management (Part I: From Etiology to Diagnostic Strategies). *Circulation*. 2003; 108:628–635.
15. Coady MA, Rizzo JA, Goldstein LJ, Elefteriades JA. Natural history, pathogenesis, and etiology of thoracic aortic aneurysms and dissections. *Cardiol Clin*. 1999 Nov; 17(4):615-35.