

# ADDUCTOR CANAL AND SUPERIOR LATERAL GENICULAR NERVE INJECTIONS FOR GRADE 4 KNEE OSTEOARTHRITIS: A CASE REPORT

**Nik Nabil WN<sup>1,2</sup>, Mohd Mustafah N<sup>1,3</sup>, and Ghazali AI<sup>1</sup>**

<sup>1</sup>Pain Management Clinic, Department of Anesthesiology and Intensive Care, Hospital Taiping, 34000 Taiping, Perak, Malaysia

<sup>2</sup>Department of Anesthesiology and Intensive Care, Hospital Kuala Lumpur, Jalan Pahang, 50586 Kuala Lumpur, Malaysia

<sup>3</sup>Department of Rehabilitation Medicine, Faculty of Medicine, Universiti Teknologi MARA, 47000 Sungai Buloh, Selangor, Malaysia

## **Correspondence:**

Nadia Mohd Mustafah,  
Department of Rehabilitation Medicine,  
Faculty of Medicine,  
Universiti Teknologi MARA,  
47000 Sungai Buloh, Selangor, Malaysia  
Email: nadiamustafah@gmail.com

## **Abstract**

This case report showcases the successful use of a combination of adductor canal (AC) and superior lateral genicular nerve (SLGN) injections in a patient with refractory knee pain caused by knee osteoarthritis (OA). A 73-year-old man with Kellgren and Lawrence (KL) Grade 3-4 of bilateral knee OA experienced debilitating chronic right knee pain and declined surgery intervention. He reported significant pain relief, which improved his ability to walk, after receiving a combination of AC and SLGN injections with a mixture of local anesthetic and steroids. This followed the unsuccessful provision of multiple analgesics and intraarticular injections. The pain-relieving effects persisted until his 2-month follow-up. Repeated injections were performed 4 months after his initial intervention, with the analgesic effect lasting for another 2 months. This case report suggests that the combination of AC and SLGN injections could be a viable treatment for patients with knee OA KL Grade 4 who are not candidates for surgery.

**Keywords:** Knee Pain, Local Anesthetic, Peripheral Nerve Blocks, Steroid

## **Introduction**

Globally, knee osteoarthritis (OA) is one of the leading causes of disability, ranking along with low back pain and neck pain (1). Although total knee arthroplasty (TKA) is generally considered safe for the geriatric population, some are hesitant to undergo the procedure due to concerns about minimal functional improvement and potentially more severe complications (2). On the other hand, two-thirds of the population perceive TKA as the befitting intervention for individuals in good health but sustaining uncontrolled pain and severe mobility issues (3). Therefore, non-surgical treatments are indispensable for improving health-related quality of life in patients who opt not to undergo TKA. Alongside advocating for exercise, weight loss programs, non-steroidal anti-inflammatory drugs (topical and oral), opioids, and intraarticular injections (4), interventions involving adductor canal (AC) and genicular nerves are gaining popularity for treating knee pain caused by knee OA (5-7). In this report, we described the successful use of injecting a mixture of local anesthetic and steroids into the AC and superior lateral genicular nerve (SLGN) in treating a patient with intractable knee OA pain.

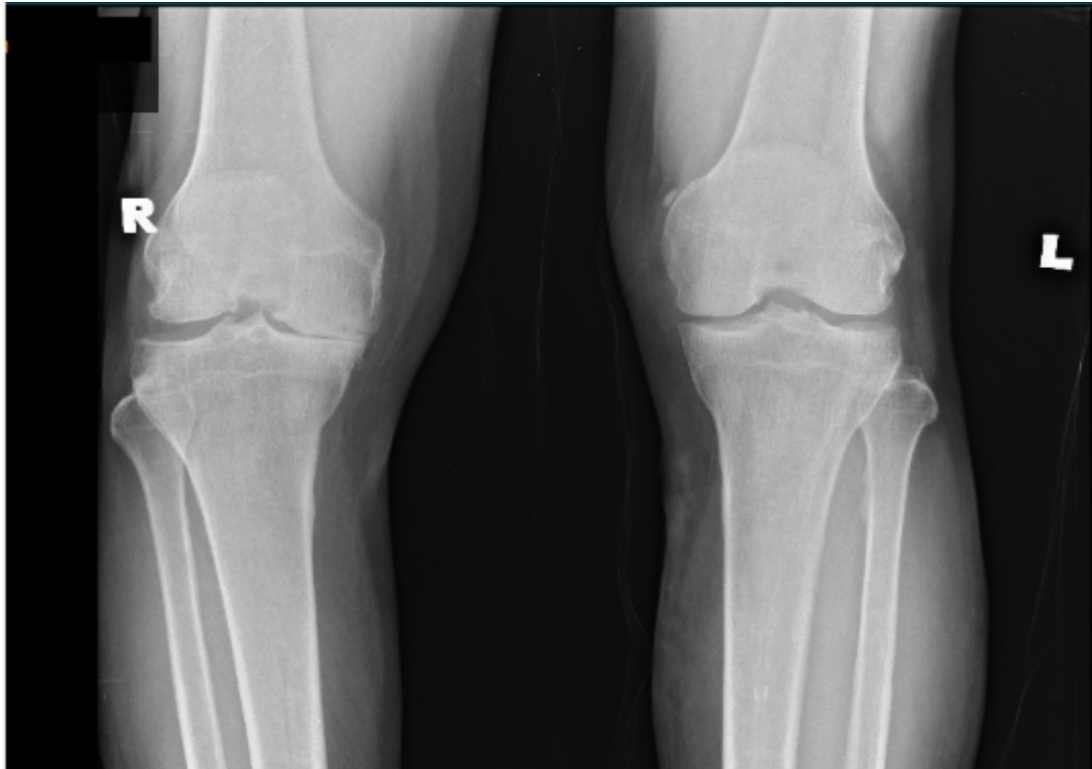
## **Case presentation**

The patient provided both verbal and written informed consent, and Institutional Review Board (IRB) review was exempted as per our institution's policy. A 73-year-old man with underlying hypertension, chronic kidney disease, and dyslipidemia presented at our clinic with chronic right knee OA. We recommended a referral to the orthopedic department for a potential TKA, but he declined due to logistic and social reasons. He was prescribed oral acetaminophen 1 gram twice daily (BID), oral pregabalin 75mg BID, lignocaine patch 5%, and diclofenac gel. However, the pain, particularly at the medial portion of his right knee, was inadequately controlled. Furthermore, he did not experience significant relief from various treatments he had undergone over the past two years, including steroid and platelet-rich plasma injections.

During the examination, both knees were neither swollen, warm, nor erythematous. The patient had a full range of motion, except for a 10-degree flexion contracture and genu varus in his right knee. The right medial knee joint lines were tender. He reported moderate pain (scoring

4/10 on the Numerical Rating Scale, NRS) and required a single-point stick to walk indoors and outdoors. X-ray

of his bilateral knees showed Kellgren and Lawrence (KL) Grade 4 (Figure 1).



**Figure 1:** Standing X-ray of both knees (anteroposterior view).

Based on the patient's previous failed intraarticular injections and the primary site of pain, we proposed a combination of AC and SLGN injections. After obtaining the patient's consent, we proceeded with ultrasound-guided injections of AC and SLGN. A total of 10ml of 10mg of triamcinolone in 0.25% ropivacaine was administered to the patient's right AC (Figure 2), and a total of 2ml of 5mg triamcinolone in 0.25% ropivacaine was administered to his right SLGN (Figure 3).

His reported pain decreased to 1/10 post-procedure, which remained stable at this level until his 2-week follow-up. He mainly required a single-point walking stick and occasionally ambulated without a walking stick with mild pain (1/10 on the NRS). His pain score remained low during the subsequent 2-month follow-up. Repeated injections with a similar solution were administered 4 months after his initial intervention as his pain recurred to 4/10 on NRS, and the analgesic effect lasted for another 2 months.

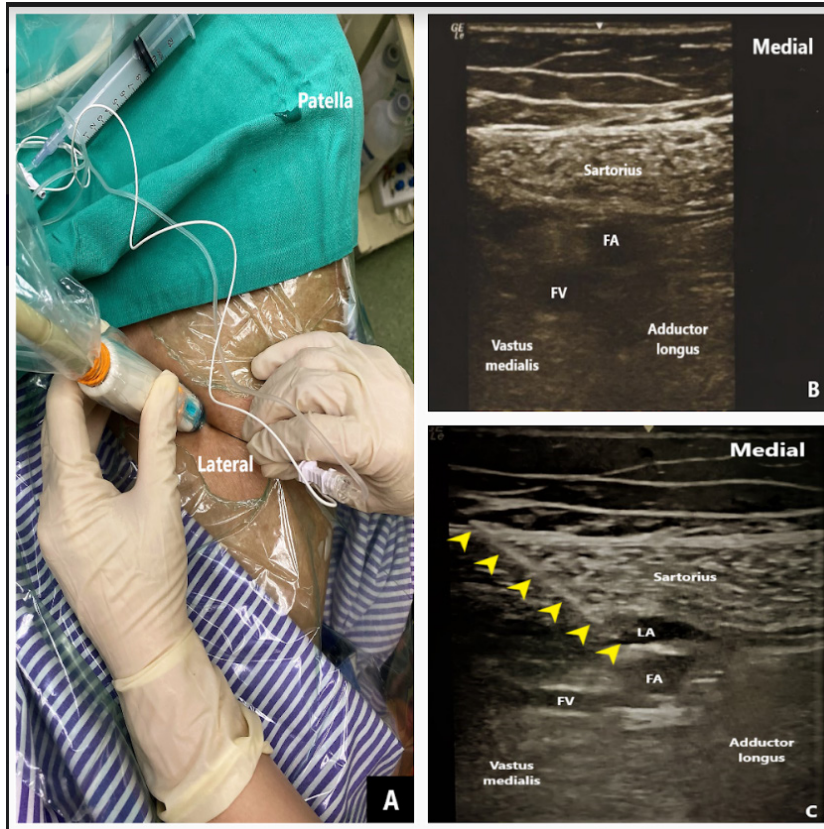
### **Discussion**

The global prevalence of knee OA is 16.0%, with the highest incidence among those aged 70–79 (8). Moreover, over half of all OA patients will eventually undergo TKA, with the highest rates observed among those aged 70-79 years (9). Regardless of the treatment received, whether TKA, non-surgical interventions, or printed information

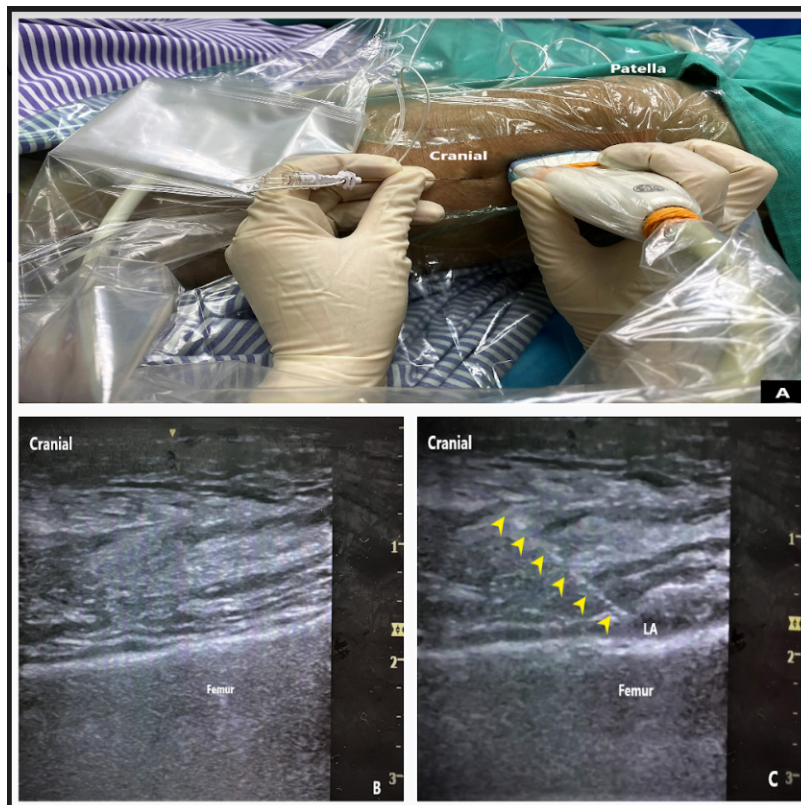leaflets, about 50-70% of patients will experience a 15% improvement in their condition 2 years post-diagnosis (10).

We decided to explore non-surgical methods to improve the patient's disability. Given that the patient experienced localized pain in the medial compartment anteriorly, we administered an AC injection to the patient. AC injection provides excellent analgesic effects to the anterior knee compartment without motor blockade (11) and demonstrates high success rates when guided by ultrasound (5). Lee et al. (6) were the first to report the efficacy of AC injection following failed conservative treatments, particularly in reducing pain scores for up to 1 month as well as lowering opioid consumption for up to 2 months. The ineffective conservative treatments included rehabilitation, pharmacology, and intra-articular (IA) injection. Ming et al. (5) further demonstrated that AC block provides longer-lasting analgesia with the improvement of quality of life for up to 3 months compared to IA injection. Both studies included KL Grade 2 to 4 patients.

The rationale for coupling AC injection with SLGN in this patient is to provide additional analgesic effects in the anterior compartment of the knee, especially since the X-ray revealed reduced joint space slightly crossing the midline to the lateral compartment. This takes into account that the AC's saphenous nerve supplies the anteromedial part of the knee joint. In contrast, SLGN (a branch of the



**Figure 2:** (A) Probe positioning and needle insertion for the right adductor canal injection. (B) Sonoanatomy of the adductor canal at mid-thigh. The saphenous nerve lies lateral to the femoral artery (FA). (C) Needle trajectory (yellow pointed arrow) and the distribution of local anesthetic (LA) following 10 mls of solution injection. FV-femoral vein.



**Figure 3:** (A) Probe positioning and needle insertion for the right superior lateral genicular nerve block. (B) Sonoanatomy of the superior lateral genicular nerve injection. (C) Needle trajectory (yellow pointed arrow) and deposition of local anesthetic (LA) above the femur for the superior lateral genicular nerve injection.



femoral nerve) supplies the anterior knee compartment superolaterally (7). Furthermore, selecting a motor-sparing injection is crucial since knee OA is known to cause quadriceps weakness (12), and any additional weakness, albeit temporary, could increase the risk of falling.

The use of glucocorticoids for peripheral nerve blocks has been a subject of debate due to a lack of understanding of their exact mechanism and site of action. The therapeutic effect of glucocorticoids is believed to be primarily due to their anti-inflammatory properties. However, evidence suggests that glucocorticoids directly affect neurons, as evidenced by the discovery of neuronal glucocorticoid receptors on sensory neurons (13). Animal studies have also shown that dexamethasone can reduce blood flow to the nerves, while methylprednisolone affects C-fiber rather than A-beta fiber, resulting in reduced heat hyperalgesia and mechano-allodynia (14). Considering this, we decided to proceed with glucocorticoid injection instead of relying solely on local anesthetic agents.

In conclusion, this case report shows that the combination of AC and SLGN injections may become a viable treatment option for patients with knee OA KL Grade 4 who are unsuitable candidates for surgery or have chosen not to undergo surgery.

### **Acknowledgment**

We would like to acknowledge KUP Nor Azuwa Junus for helping us throughout the procedure and record keeping.

### **Competing interests**

The authors declare that they have no competing interests.

### **Ethical Clearance**

We obtained the patient's written consent for the publication of this case.

### **Financial support**

No funding was received for this work.

### **References**

1. Neogi T. The epidemiology and impact of pain in osteoarthritis. *Osteoarthritis Cartilage*. 2013; 21(9):1145-1153.
2. Cheung A, Fu H, Cheung MH, *et al*. How well do elderly patients do after total knee arthroplasty in the era of fast-track surgery? *Arthroplasty*. 2020; 22(1):16.
3. Hawker GA, Wright JG, Badley EM, Coyte PC. Perceptions of, and willingness to consider, total joint arthroplasty in a population-based cohort of individuals with disabling hip and knee arthritis. *Arthritis Rheum*. 2004; 51(4):635-641.
4. Arden NK, Perry TA, Bannuru RR, *et al*. Non-surgical management of knee osteoarthritis: comparison of ESCEO and OARSI 2019 guidelines. *Nat Rev Rheumatol*. 2020; 17(1):59-66.
5. Ming LH, Chin CS, Yang CT, Suhaimi A. Adductor canal block versus intra-articular steroid and lidocaine injection for knee osteoarthritis: a randomized controlled study. *Korean J Pain*. 2022; 35(2):191-201.
6. Lee DH, Lee MY, Kwack KS, Yoon SH. Effect of adductor canal block on medial compartment knee pain in patients with knee osteoarthritis. *Medicine (Baltimore)*. 2017; 96(12):e6374.
7. Ahmed A, Arora D. Ultrasound-guided radiofrequency ablation of genicular nerves of knee for relief of intractable pain from knee osteoarthritis: a case series. *Br J Pain*. 2017; 12(3):145-154.
8. Cui A, Li H, Wang D, Zhong J, Chen Y, Lu H. Global, regional prevalence, incidence and risk factors of knee osteoarthritis in population-based studies. *EClinicalMedicine*. 2020; 29-30:100587.
9. Weinstein AM, Rome BN, Reichmann WM, *et al*. Estimating the burden of total knee replacement in the United States. *J Bone Joint Surg Am*. 2013; 95(5):385-392.
10. Skou ST, Roos EM, Laursen MB, *et al*. Total knee replacement and non-surgical treatment of knee osteoarthritis: 2-year outcome from two parallel randomized controlled trials. *Osteoarthritis Cartilage*. 2018; 26(9):1170-1180.
11. Kukreja P, Venter A, Mason L, *et al*. Comparison of genicular nerve block in combination with adductor canal block in both primary and revision total knee arthroplasty: a retrospective case series. *Cureus*. 2021; 13(7):e16712.
12. Chin C, Sayre EC, Guermazi A, *et al*. Quadriceps weakness and risk of knee cartilage loss seen on magnetic resonance imaging in a population-based cohort with knee pain. *J Rheumatol*. 2018; 46(2):198-203.
13. Shaqura M, Li X, Mahmoud Al-Khrasani, *et al*. Membrane-bound glucocorticoid receptors on distinct nociceptive neurons as potential targets for pain control through rapid non-genomic effects. *Neuropharmacology*. 2016; 111:1-13.
14. Hewson D, Bedforth N, McCartney C, Hardman J. Dexamethasone and peripheral nerve blocks: back to basic (science). *Br J Anaesth*. 2019; 122(4):411-412.